

MAX DAUNDERER M.D.

A M A L G A M

Original Title : " Amalgam "

6th Edition 2000

(c) ecomed , Landsberg , Germany

Translation : Georg Schmidt

CONTENTS

1	HISTORY
1.1	Clinical toxicology
1.2	Amalgam poisoning - definition
1.3	Caries
1.4	The intelligent patient
1.5	Inherited poisoning
2	COMMONNESS
2.1	Occurence
2.2	Ingestion
	EFFECT AND ACTION
3.1	Components
3.1.1	Tin
3.1.2	Copper
3.1.3	Silver
3.2	Effect amplification
3.2.1	Additional poisons
3.2.1.,1	Alcohol
2	Aluminium
3	Car emissions
4	Dioxins
5	Formaldehyde
6	Gold
7	Ceramics
8	Lindane
9	Palladium / titanium
10	Passive smoking
11	Pentachlorophenol (PCP)
12	Pyrethroids
13	Environmental toxins
14	Home toxins
15	Dental toxins
16	Other poisons
3.2.2	Other factors
3.2.2 .1	"Dead teeth"
3.2.2 .2	Impacted wisdom teeth
3.2.2 .3	Electromagnetic fields
3.3	Injurious mechanisms
3.3.1	Attack points of mercury in the cell
3.3.2	Amalgam allergy
3.3.3	Autoimmune diseases
3.4	Symptoms
3.5	Amalgam career
3.6	Dental foci
3.7	Metabolism anomaly
3.8	Degree of poisoning

3.9 "Advantages"of amalgam

4 CLINICAL PROOF

- 4.1 Proving the toxin
 - 4.1.1 Chewing-gum test
- 4.2 Proof of poison assimilation
 - 4.2.1 Advice
 - 4.2.1.1 Orthopantomography (OPT)
 - 4.2.1.2 MRI of brain
 - 4.2.2. Proof
 - 4.2.2.1 DMPS test
 - 4.2.2.1.1 Injection
 - .2 Creatinine
 - .3 Crgcnic mercury
 - .4 DMPS capsules
 - 4.2.2.2 DMSA test
 - 4.2.2.3 Laboratory analysis
- 4.3 Proof of toxic effects
 - 4.3.1 Allergy tests : patch test
 - 4.3.1.1 Amalgam tests
 - .2 Tests for metals and adhesives
 - .3 Tests for home toxins
 - .4 Therapeutica
 - 4.3.2 LTT (lymphocyte transformation test)
 - 4.3.3 Blood tests
 - 4.3.3.1 Alphc-1-microglobuline
 - 4.3.3.2 Glutathione-sulphur-transferase (GST)
 - 4.4 Proof for eure

5 THERAPY

- 5.1 Exposure stop
 - 5.1.1 Amalgam removal
 - 5.1.1.1 Pregnancy and lactation period
 - 5.1.2 Restoration of dental focus locations
 - 5.1.2.1 Surgical methods
 - .2 Therapeutic proceasure for foci and teeth
 - .3 Convalescence time
- 5.2 Depot detoxification
 - 5.2.1 DMPS
 - 5.2.1.,1 " sniffing
 - .2 Jawbone detoxification
 - ,3 DMPS dosage
 - ,4 " allergy
 - ,5 Trace element count
 - 5.,2.2 DMSA
 - 5.,2.,2.,1 " sniffing
 - ,2 " allergy
 - .3 Infant detoxification
- 5.,3 Therapy for environmen
 - 5,3.,1 Zinc
 - 5,,3.,2 Selenium

- 5.4 Detoxification of environmental poisons
- 5.4.1 Ginkgo biloba
- 5.4.2 Calcium antagonist
- 5.5 Metal intolerance
- 5.6 Senseless therapies
- 5.7 Ten rules for amalgam victims

6 ALTERNATIVES

- 6.1 Contraindications for dental materials

7 THERAPY RESULTS

- 7.1 Allergies, Fear, MCS
- 7.2 Lack of drive - depression
- 7.3 Abdominal pain
- 7.3.1 Liver damage
- 7.3.2 Pancreatic inflammation
- 7.4 Splenic disorders
- 7.5 Blood count abnormalities
- 7.6 Depression, psychosis
- 7.6.1 Drug addiction
- 7.7 Diarrhea
- 7.8 Epilepsy
- 7.9 Memory disfunctions
- 7.10 Joint pain
- 7.11 Hair loss
- 7.12 Heart infarction, heart rhythm disorders
- 7.13 Non-resistance to infections
- 7.14 Infertility, impotence
- 7.15 Interactions
- 7.16 Headaches
- 7.17 Cancer
- 7.18 Paralysis, MS, ALS
- 7.19 Muscle weakness
- 7.20 Pregnancy
- 7.21 Vertigo
- 7.22 Vision, hearing and speech disorders
- 7.23 Fatalities, crib death
- 7.24 Trembling
- 7.25 The constant complainer
- 7.26 Psychosomatics

Introduction

When you read this book for the first time, you are likely to be surprised by the author's directness.

In the face of the suffering that he has witnessed in many years of practice, Dr Daunderer has become an outspoken advocate for the victims, and it is out of concern for them that he does not mince his words.

Since this booklet is not addressed to the medical professional, but rather to the patient (the first editions were named "Amalgam - Information for Patients"), it focuses on explaining the methods and effects as they are relevant to the layperson. It does not devote space to documenting clinical evidence and therapy results, about which the author is often asked. They can be found in his 2200 page "Handbook of Amalgam Poisoning", available - so far only in German - directly from Dr Daunderer .

My gratitude goes to Dr Max Daunderer for his help with this translation, and to Heinz Pscheidl for the inspiration to do it. May it help to disperse the heavy gray cloud over our lives that we call amalgam .

Georg Schmidt, Jerusalem, October 2000

It was in the year 1840 that amalgam was first outlawed in the USA. Over a period of 15 years, any dentist using amalgam was expelled from the professional association.

Since then a desperate battle of the amalgam victims against the profiteers has raged.

Until we proved with the chewing-gum test, that amalgam poisons the saliva, the official statement was that the toxic metals mercury, tin, copper and silver are not released from amalgam fillings, which were said to be stable.

Mercury in amalgam fillings is like a time bomb : the unsuspecting think that the danger will stay in its Shell. Until we were able to prove the organ deposits through DMPS-testing, it was claimed that almost all the toxins are excreted, and that the intake of poison was far below any tolerance limits. Health improvements in our patients were dismissed as "psychological". In spite of 25 publications proving the opposite, 60 "specialists" claimed at the amalgam hearing in München on Sept 15 1989, that anorganic mercury is not changed into organic mercury in the organism. As of today, all has been clearly rectified, and the global poisoning of the population is now inspired only by the claim that this is the cheapest repair method. This, although it is known worldwide, that because of the high medical follow-up costs, the use of amalgam turns out to be the most expensive dental repair method by far.

Globally, the ratio of multiple sclerosis cases correlates exactly with the amount of mercury used by dentists. Without amalgam, MS would be unknown. The mother's amalgam determines the development of the disease (Feer-syndrome).

The mercury content in sweetwater fish also correlates with the amount of mercury used by dentists. The more amalgam is used, the higher the toxic intake through our food.

Eminent warnings against mercury are not new: In 1874 J. Payne, a dentist, wrote in the Chicago Medical Journal: " There *are* 12 000 dentists in the USA who are wholesale dealers of this poisoning (by amalgam), and I request the Cooperation of the National Medical Association as guardian of the public health, to aid in having Congress pass a law to the effect, that whoever installs in teeth a substance that will cause damage to humans, is punishable by jail." (not the original text, G.S.)

Prof. STOCK, then director of the Max-Planck-Institut and professor of chemistry, learned as early as 1910, from the greatest clinical toxicologist in Germany, Prof. LEWIN, that he would be cured of his Feer Syndrome - disorders in the central nervous System caused by liquid mercury vapors at his workplace - only if he had his amalgam fillings removed.

After their removal, Stock felt like a new man and tried to prevent all dentists from continuing to poison their patients. The dentists tried to delay the prohibition of amalgam. They founded an institute in Berlin to investigate Stock's claims. After 10 years, this institute declared that Stock's warnings "of the worst sins against mankind through amalgam" were correct, and that "amalgam should be avoided at once as soon as an alternative is found". Since then, the culprits pretend to be deaf.

Alternative materials were known at the time: gold for the rich, mineral cements for the poor, but this knowledge became obscure under Hitler's laws, which demanded exclusive use of amalgam. As a result, it was used without protest for filling cavities and even as denture modelling material. Mercury was in unlimited supply, being a byproduct of the arms-producing chloric chemistry.

In the 1960's the dentists argued as if Stock had never existed.

It is really unforgiveable, that sick patients are deliberately kept ignorant about the necessity of a thorough removal of amalgam and gold in cases of diseases of affluence caused by autoimmune disorders (allergies), and that other allergens must not be used in their stead.

In the country of origin of the chemical industry, Germany, amalgam poisoning is unrecognized officially - 'persona' non grata. Patients are regarded as mentally ill and the helpers as enemies of the establishment. Since noone knows about their toxic effects, dentists use the absolutely contraindicated antagonists palladium or platinum in replacing the fillings. The patient, who becomes even sicker now, is ridiculed as a hypochondriac. Only the patient that looks for information himself has a chance of becoming well again.

Because the components of amalgam are accumulated under the dental roots and cause harmful bacteria and fungi to grow there, the result is always a loss of teeth and damage to organs and/or the nerves related to this particular inflammation focus. This is very bitter for the patients and difficult to understand.

The effects of the poisoning, for example the inflammations under the teeth, determine the diseases, not the amount of fillings in your mouth.

Amalgam, once put in, has lifelong effects - even after removal; it is the most common cause of death. The person that understands what amalgam is and what it does, will never permit a depot of poison to be installed in his organism.

The history of amalgam shows that only the intelligent, well-informed patients stand a chance of being protected from poisoning, or being saved.

This text is based on experience with more than 20.000 patients.

1.1

Clinical Toxicology

Clinical toxicology is the pivotal point of medicine; it is the doctrine concerning life under known, disease-causing conditions.

Ignorant people consider clinical toxicology to be quackery.

The author qualified for university lecturing, as clinical toxicologist, at the Technical University München and draws his knowledge from more than 25 years of experience as emergency doctor for the fire brigade, in helicopter rescue and as emergency doctor for toxicology in private practice, as senior physician of a large toxicological department of the university and from international service at sites of poisoning catastrophes (Seveso, Italy and Bhopal, India) for the German government. He has been witness to more than 120.000 serious cases of poisoning, among them over 5.000 fatalities.

It is only when we see the physician stand helpless in front of the patient at the end of a long history of poisoning that we understand, how important prophylaxis is, which we can learn from clinical toxicology.

Since the ratio of victims of chronic poisoning to acute poisoning is about 100.000 to one, only the knowledge about chronic poisoning - and especially about environmental toxins - is relevant to humankind. Only improvement of symptoms after complete removal of toxins can prove a case of chronic poisoning.

Since our jawbones assimilate mostly those toxins that are inhaled through the nose, the toxicologist deals not only with the effects of car emissions, home toxins and pesticides, but also with the dental repair materials that the jawbones assimilate.

It remains incomprehensible for a clinical toxicologist, how one can

fill several grams (!) of highly toxic, liquid mercury into people's teeth, and then declare as final proof for its harmlessness, that the removal of amalgam (which is incomplete without antitoxins) will not restore the health of patients with mercury symptoms - even though this is impossible with any dangerous poison: there is always a likelihood of permanent organ damage through toxins.

Modern clinical toxicology possesses all the means for proving the toxin, its action and effects. In particular, the proof of the genesis of auto-immune diseases as a result of amalgam gives evidence of the ^{causal} connection of amalgam to "diseases of affluence". Patients afflicted with auto-immune disorders are, apart from the newborn children of amalgam carrying mothers, the most deplorable victims of amalgam - in most cases they can achieve substantial health improvement only by sacrificing all of their teeth.

Doctors are not trained to recognize and treat an amalgam poisoning.

Exact knowledge about the acute poisoning is the prerequisite for understanding the chronic effects of a poison, which has a completely different character: for example, acute alcohol intoxication induces unconsciousness while chronic alcoholism induces states of excitation. Acute nicotine intoxication is stimulating while a chronic effect can be infarction.

Generally, chronic is confused with acute poisoning. This is just as wrong as trying to explain a smoker's diseases after decades with the acute effects of nicotine.

The non-existent training for treatment of poisoning prohibits all use of toxins .

1.2 Amalgam Poisoning - Definition

Amalgam poisoning is a chronic poisoning, where acute blood or urine readings are mostly normal.

The mechanism of chronic amalgam poisoning combines a poisoning with a genetically fixed attack on more than 60 relay points of sulphur in

the acetyl coenzyme A - sulfhydryl group and with an allergy against the assimilated poison, which, after decades, causes auto-immune diseases.

The poisoning and blockade of the sulfhydryl group cause the disorders in the nervous system; immune system symptoms are caused by the allergy and auto-immune disease in its wake.

This allergic reaction turns against the organism's own, individual organs and destroys them, if the causes are not eliminated completely and in time. Allergic reactions run according to the law of all-or-nothing, and not according to any limit values, this is why the battle of the therapists and patients to try and remove all toxins at their source and from their depots in the body is often a desperate one. It can succeed only if all causes and effects are identified and removed by specialists, often requiring much technical effort.

Many children are already born with an amalgam allergy and auto-immune disease, caused by the amalgam received from the mother via the placenta or the milk. Child amalgam poisoning is the tragic root of the amalgam problem, especially because so far we have not found one person in Germany without this "inheritance" .

Not only financial questions are of importance here, but also, especially the problem of releasing the toxins from their body depots, which can pose a potentially deadly risk for patients with allergy and auto-immune disorder. It is also not so that there are an unlimited number of specialists around for everyone of these problem cases.

Dental amalgam, like gold, is also the cause for many modern diseases like cardiac infarction, stroke, multiple sclerosis, diabetes mellitus, rheumatism and Cancer.

In official language a poisoning is called a "stress factor".

Genuine cause removal is purely a matter of luck.

1.3 Caries

Caries is a metabolic disease with an immunodeficiency against the oral germ *Streptococcus mutans*, which destroys the tooth beneath the enamel. Dental hygiene and avoiding sugar help a little, but do not affect the cause at all.

The preservation of teeth can be achieved only by removing the cause and stabilizing the immune system through vaccination against the caries germ. Plugging the cavities with allergenic and toxic substances leads to a further weakening of the immune system and progress of the disease with tooth deterioration.

Amalgam has antibiotic properties. After some time, caries germs, dangerous resistant bacteria and fungi grow under the amalgam and cause decay. They destroy the periodontium and the jawbone. This inflammation focus, the toxic focus, constitutes the disease trigger.

Amalgam destroys teeth and causes disease.

Amalgam occupies the detoxification enzymes, for this reason all of the inhaled poisons are assimilated in the dental roots. The amalgam and these depot toxins with time act like immune toxins. The process is speeded up by lack of physical exercise (aiding detoxification) and ^anutrition poor in vitamins (which causes ^alack of detoxification enzymes).

Repairing cavities cannot replace removal of cause.

± The suffering can be reversed only by exact retracing of its path:
Removal of the patient from the toxic environment

↓
Surgical removal of toxin depots

↓
Chemical drainage of toxin depots

↓
Nutrition rich in vitamins

↓
Physical exercise

↓
Joy of living

1.4 . The Intelligent Patient

Only an intelligent person will understand the long-term damage caused by metals and the toxin foci that develop in their wake. The others are content with the cheapness of their dental treatment and the absence of pain, the nerves being numbed by the metals. And brushing the teeth becomes unnecessary. Smokers and constant complainers lack the necessary insight. Amalgam victims can be like a smoker who continues to smoke even after the amputation of a leg, saying "it won't do me any harm".

"Whosoever claims that poisons cannot harm him, is mistaken"(Lewin,1866). Among those who say " Yes, but I don't have any complaints" we find the schizophrenics with split personalities, caused by the amalgam-related glutamate disorder. Only intelligent women know, for example, that it is the size of a painless knot in the breast that determines life expectancy with a breast cancer (over 2 cm less than 5 years, under 1 cm up to 30 years).

1.5 Inherited Poisoning

Children inherit amalgam from their parents, partly in substance form, partly as a genetical defect. Only mothers that do not undergo a correct amalgam therapy in time, pass the poison onto their children.

Illustration 1 : Amalgam poisoning of newborn children

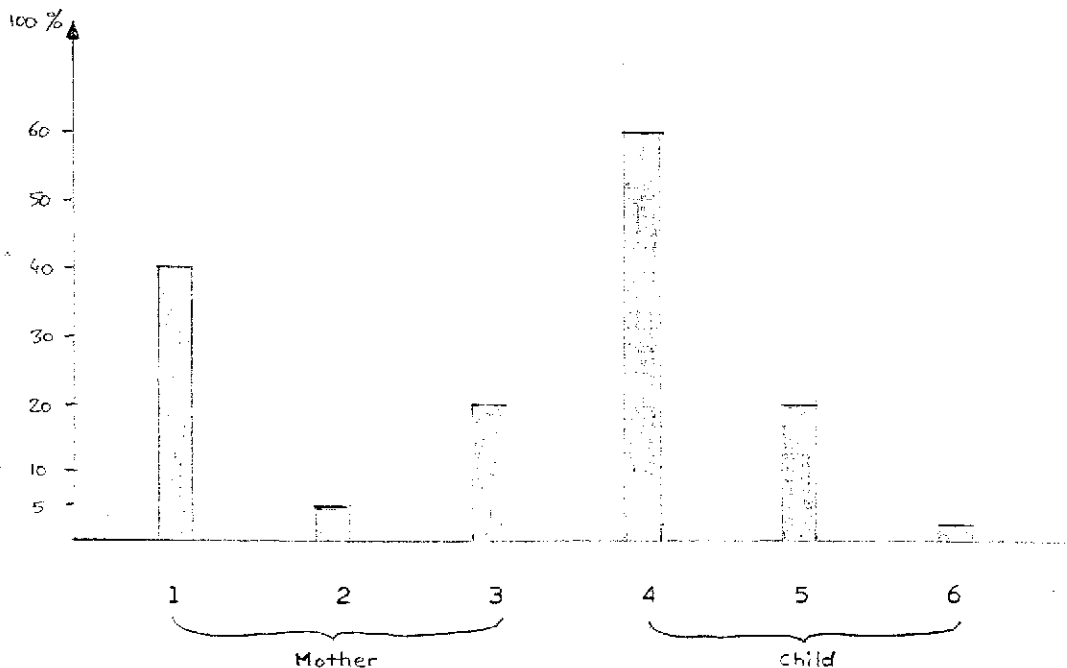


Illustration 1 :

Amalgam depots in the organism of a mother after

- the first child 1 after pregnancy
- 2 after 3 months breastfeeding
- the second child 3 after pregnancy

Child after amalgam therapy of mother

- 4 without protection
- 5 with protection and one year of detoxification
- 6 with protection and three years "

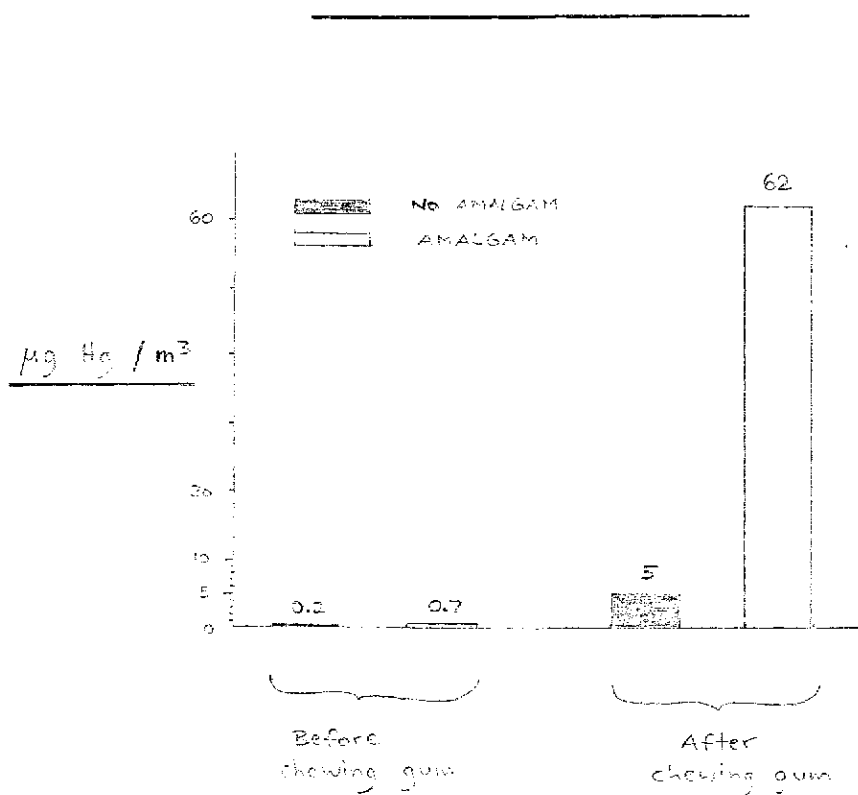


Illustration 2 : Mercury content in saliva

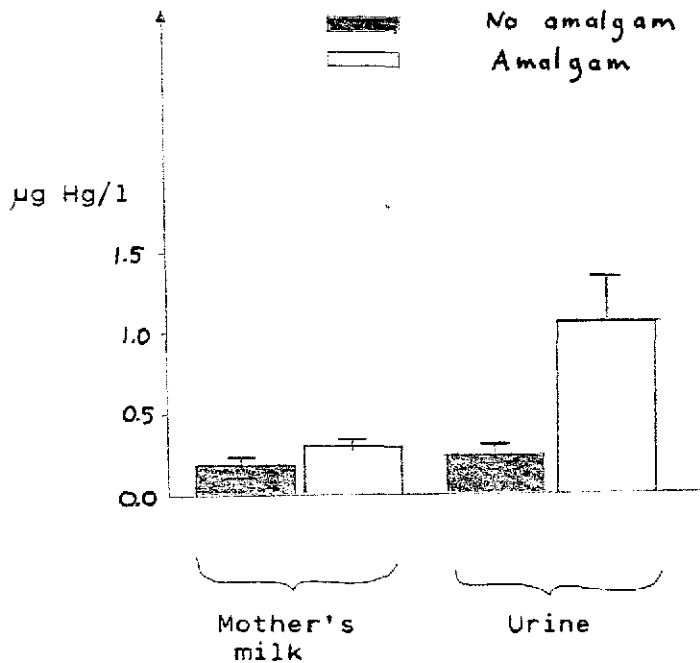


Illustration 3 : Mercury content in mother's milk and urine

Pediatricians almost only see newborn children with amalgam-related nerve or immune damage, and have come to terms with this.

2 COMMONNESS

We know of no one in Germany without maternal amalgam.

Maternal amalgam is the major poison source. Up to 40 % of the total amount of poison that is stored in the mother's organism, is passed on to the child during pregnancy, an additional 5 % during breastfeeding,

The children of mothers with amalgam fillings develop caries as a result of the mother's previous damage, the child's caries is then again treated with amalgam fillings, although in most cases an allergy against amalgam (including the mother's auto-immune disease) already existed.

Prior to their falling out, mercury is assimilated from amalgam-filled teeth by the jawbones of the child, and is then built into the permanent teeth.

Amalgam is left under about 60 % of gold crowns (recognizable by the local bone atrophy and metal foci at the roots).

We have had amalgam removed, that contained not only mercury, zinc, silver, palladium, indium, tin and copper but also lead, cadmium or gallium (which had caused the most severe allergies).

The release of amalgam is much increased, if other metals are adjoining to or opposite the filling (battery-effect), or upon contact with hot drinks, acidic foods (vinegar) and especially by grinding the teeth.

Fluoride, from toothpastes or the "protective" dental laquer, transforms the mercury into the highly toxic organic mercury, which is absorbed rapidly and, in particular, poisons the brain.

2.1 Occurrence

Over the last 25 years we were unable to find anyone in Germany, who was free of amalgam: 95 % had it themselves, 5 % had received it from their mothers during pregnancy (Feer-syndrome).

2.2 Ingestion

The amalgam components are set free when laying the fillings and when removing them, and every day by chewing, through contact with hot liquids, acidic foods and especially by tooth brushing and grinding.

The strongest toxic effects are caused by the mercury vapor which enters the brain, forming deposits that cannot be removed .

The swallowed amalgam causes local irritation along the whole digestive tract. Intestinal bacteria as well as fungi (candida) transform the less harmful anorganic metal into the highly toxic organic metal (methyl mercury / tin), which is assimilated by the brain at once and causes the most severe nerve damage.

The amalgam that is excreted through the urine, causes inflammation of kidneys and urinary tract.

Assimilation in % : 60 % in vapor form into the brain

20 % through the digestive tract into the brain
in methylated form

20 % excreted through the bowels

This assimilation ratio is affected negatively by the simultaneous presence of other metals in the mouth:

Gold, palladium, nickel (braces for children) considerably increase the mercury release because of the battery-effect; the extent depends on the acidity of the saliva. Exact data about this does not exist. What is known is that here the allergy ratio is especially high and that many metals are assimilated in the organs.

EFFECT AND ACTION

The toxicity of amalgam is not determined by mercury alone. We are dealing with a Compound poisoning. This multiplies the probability of damage to the metabolism and of the allergy ratio.

Amalgam, the metallic-gray dental filling material, contains at least 50 % liquid mercury, the other half consists of about a third each of tin, silver and copper shavings. The liquid mercury is mixed with the shavings by the dentist just before use. The soft "putty" is then stuffed into the cavity. Over the next days the material hardens more and more as the mercury evaporates and is swallowed. Amalgam always remains a relatively soft metal mixture, from which the metals are separated by heat, acids and mechanical action. In Germany alone, more than 20 tons of mercury amalgam are plugged into teeth every year (in 1989 37.8 million amalgam fillings were laid).

The dangerous mercury is that which is found in the body depots (jawbones, brain-j-etc.), not the mercury detectable in blood, urine or hair.

A quarter of the German population is missing an enzyme that helps in mercury detoxification - Glutathione sulfur transferase (GST). Only if this detoxification enzyme is present in the body in sufficient quantities, does the organism tolerate amalgam for a longer time.

Even if the greater part of the mercury is excreted by an intact detoxification System, it has already caused damage. Assimilated mercury always causes damage, which, in a healthy person, can possibly take up to 30 years to surface. Where, when and which damage occurred, becomes clear only in the aftermath. The list of toxic foci in chapter 3.6.1 gives indications here.

Mercury sensitivity is increased in :

- | | |
|-------------------------|---|
| - unborn children | - thinnerpoisoned people (paint solvents) |
| - babies | - alcoholics |
| - infants | - smokers |
| - girls | - cancer patients |
| - slim people | - formaldehyde poisoned people |
| - metal-poisoned people | - wood preservative " " |

First amalgam makes mentally ill, then physically.

Indicators of a poisoning are :

- chronic fatigue varying with irritability
- hair loss
- headaches
- acne
- vertigo
- nervousness
- trembling
- depression
- stomach / digestive trouble
- ataxia
- memory defects
- paralysis
- sleeping problems
- numbness
- metallic taste
- visual / acoustic disorders
- muscular weakness
- immune deficiency
- backaches
- heart rhythm disorders
- allergies
- anaemia
- fatigue

3.1 Components (5.000 patients)

Component	Allergy	Immune disorder	Nerve disorder
Lead	30 %	+	+++
Cadmium	30 %	+	++
Copper	20 %	+ liver	+
Palladium	70 %	+++	++
Silver	20 %	+	+++ pain
Mercury	95 %	+++	+++
Tin	70 %	+	+++
Zinc	30 %	++	+

3.1.1 Tin

Action : tin is assimilated in the body much like mercury.

Indicators of a poisoning are :

- increasing weakness
- headaches
- chronic fatigue
- hoarseness
- neuralgia
- coughing
- sensitivity to pain
- sensitivity to cold / to weather
- paralysis
- pallor
- increasing and diminishing pains in the digestive tract
- visual disorders
- bronchitis

Tin is a zinc-eater, it is changed by the ordinary intestinal bacterio into the extremely poisonous organic tin, the most dangerous metal we know of. Tin vapors, just like mercury vapors, are inhaled as they escape from the amalgam. The more mercury is released, the more tin is also set free. Tin is a very powerful nerve and brain poison, which simultaneously attacks the immune System. Excretion is aided by DMPS.

3.1.2 Copper

Indicators for poisoning are :

- | | |
|--------------------------|--------------------|
| - chlonic cramps | - strong trembling |
| - colics | - weakness |
| - vision disorders | - constipation |
| - breathing troubles | - allergies |
| - tooth grinding | - liver damage |
| - numbness (paresthesia) | |

Copper is very dangerous in its organic form. It causes damage to liver and brain. In water even traces of it can kill all fish. Copper drives out zinc, which is vital for the excretion of toxms.

Copper is universally used today for plumbing. When infants ingest copper with their drinking water, their liver can be damaged so much as to be fatal. Copper inhibits the excretion of mercury and zinc from the body. Beware of copper kitchenware : it is dangerous to use copper pots and pans.

Secause of the large amounts of copper in the organism and the weak effect of DMPS on copper, it cannot be flushed out of the System effectively with DMPS. One has to make sure that there is enough zinc, as a copper antagonist, in the body, by removing all zinc-eaters. Zinc-eaters are also selenium-eaters, they destroy also vitamins and damage the immune and nervous System.

3.1.3 Silver

Indicators for poisoning are :

- | | |
|--------------------------|--|
| fear | - mental weakness |
| forgetfulness | - weakness of muscles, tendons, joints |
| brain function disorders | - cartilage swelling |
| headaches | - backaches |
| vertigo | - rheumatism |
| little stress capacity | |

Silver damages the tendons, cartilage and joints and increases the toxicity of the other amalgam components. DMPS has little excretory effect on silver, zinc and selenium seem to have no effect. Sulphur, in the form of sodium thio-sulfate, reaches only the silver outside of Cells. We know very little about its exact metabolic function. The considerable concentration of silver found in the intervertebral discs of operated patients, as well as the amelioration of Symptoms in disc and knee patients that did not undergo an Operation, but rather a successful amalgam detoxification, show that silver certainly cannot be neglected as a toxic component.

We describe silver as the pain component in amalgam, it is the knife or thorn in the body. Mercury causes painless nerve damage, but silver causes extremely painful nerve damage.

Nerve and immune disorder = "psycho-somatic" = amalgam sickness

Animals with amalgam fillings also become psychosomatically sick at once, that is why veterinarians do not use amalgam anymore, since there are no hospitals for "psychosomatically ill animals".

3.2 Effect Amplification

3.2.1 Additional Poisons

3.2.1.1 Alcohol

Often an amalgam victim will try to hide the signs of his poisoning (insecurity, sleep disorders, trembling) by drinking.

Here, rare excesses are not as dangerous as the constant small doses. They stimulate the intestinal transformation processes that form organic mercury, which is primarily assimilated by the brain, permanently. This, as well as the parallel reduction of the zinc level hinder excretion and increase assimilation of mercury (and other toxins) in organs. An immediate stop of alcohol consumption achieves marked improvement in the amalgam patient's condition.

3.2.1.2 Aluminium

Sometimes dentists use aluminium caps to protect teeth temporarily. Amalgam patients often are given aluminium pills (2 grams each) for years, against their stomach aches, others eat much canned food or cook in aluminium pots. Ceramic dental material that is not sintered carefully, can release much aluminium. Proof by chewing-gum test. Amalgam patients reveal increased assimilation of aluminium in the body. Alzheimer patients showed high aluminium levels in post mortem brain analysis and had amalgam.

Many amalgam patients have very high levels of aluminium in their diseased jawbones. They exhibit extreme memory disorders after a latency period of more than 15 years. High aluminium readings in the whole blood (possibly urine) indicate a high level of acute intoxication. It is more important to stop this acute strain than to decrease the assimilation with an antitoxin (**Desferroxamine intramuscular every 6 to 12 weeks**).

Experience shows, that in cases of chronic aluminium poisoning, the removal of co-toxins like amalgam, with DN'PS, is better for the patient than the sole removal of aluminium with desferroxamine. Iron levels are greatly reduced by desferroxamine in problematic cases this must be taken into account (mainly growing children, and women).

3.2.1.3 Car Emissions

Besides lead, platinum, palladium, titanium, benzol, methanol and formaldehyde, countless substances that damage the immune and nervous systems are found in the emissions of car engines. The higher the concentration of assimilated amalgam in the body, the higher the lead assimilation in the jawbones. The more dental root canals are filled with formaldehyde, the more pronounced the formaldehyde metabolism disorder by exposure to city traffic. The driver of a car breathes the toxic emissions of the cars around him. After only 20 minutes of driving, considerable amounts of absorbed toxins can be measured in the organism. Houses on busy roads show high levels of lead, benzol, etc. in the floor dust.

The effects of the toxins are increased by way of organ damage (brain, kidneys, immune System, blood-producing bone marrow) and by damage to the excretory mechanism (lack of zinc).

3.2.1.4 Dioxins

This, the most lethal immune and nerve poison, can today be found in all the inhabitants of industrialized nations. Dioxins cause damage in any concentration. This ultra-poison multiplies the effect of amalgam.

3.2.1.5 Formaldehyde

Before, inflamed teeth were extracted; today they undergo endodontic treatment and the root canal is filled with toxic material. Until recently, arsenic was used to deaden the pulp. Today only pastes containing formaldehyde and a range of allergenic substances (Cortisone, antibiotics; are used to fill root canals.

This formaldehyde remains in the jawbone for life and is constantly released into the body. A dental root containing formaldehyde multiplies the effect of amalgam by about a hundred fold. Such constant release of formaldehyde into the blood - night and day - causes a dissimilation malfunction : folic acid, the enzyme needed for formaldehyde dissimilation, is already in demand through the presence of amalgam. Mercury also causes a genetic defect in formaldehyde dissimilation via a spot mutation. In tests (passive smoking or after folic acid pill) this shows in an increased breakdown ratio in the form of formic acid in urine (immune damage) and /or an increased rebuild ratio of methanol (nerve damage), which later once again becomes formaldehyde and formic acid. In these cases the filling has to be a laboratory-made plastic inlay. - Synthetic adhesive is recommended instead of cement. If there is a formaldehyde dissimilation disorder present, formaldehyde will cause strong nervousness and trembling, brain dysfunctions, allergies and severe immune system damage even including Cancer. Passive cigarette smoke contains especially high amounts of formaldehyde.

3.2.1.6 Gold

Gold binds amalgam. Sheet gold is the gauging tool for amalgam that dentists use in industrial medicine. Gold alloys are not suitable for replacing amalgam fillings, because they bind the amalgam depots in jawbones and brain for life. We do not tolerate platinum anymore because of the platinum emissions from catalytic Converters in the automobiles. An amalgam : Can be found under 90 % of gold crowns. These can be detected by the amalgam assimilation around the roots and the amalgam tattoo in the mucous membrane. In the healthy rat, amalgam causes autoimmune diseases, meaning lethal diseases of affluence.

3.2.1.7 Ceramics

Ceramic dental materials that are not sintered carefully (= sintered at least six times) release much aluminium - up to 31 million ug/kg per crown. The synthetic adhesives in use mostly contain formaldehyde. Proof by chewing-gum test. Many amalgam patients have a severe allergy against aluminium and formaldehyde.

3.2.1.8 Lindane

Lindane impedes the potassium / sodium / magnesium assimilating enzymes in every cell in 108 places; nerve poison; dioxin contaminated; causes leukemia. Proof as for pentachlorophenol. Allergy is confirmed by long-term allergy test.

3.2.1.9 Palladium / Titanium

Palladium is often used as a component for dental gold alloys. Amalgam poisoned patients cannot tolerate even traces of palladium. Titanium is used for implants, bridges and artificial hip joints.

In the end, the titanium and palladium emissions from automobile engines are the reason why we suddenly cannot tolerate these poisons at all anymore. The abrasion from the fillings is proven by a chewing-gum test, the allergy by a long-term allergy test. A palladium allergy (70% !) is often connected to a nickel allergy. In severe cases the tooth must be extracted and the root cavity cleaned surgically several times. DMPS can be used only after the tooth extraction, even then its excretory effect on palladium is limited. The Symptoms of palladium poisoning are almost identical to those of amalgam.

3. 2.1.10 Passive Smoking

Cigarette smoke contains more than 800 cancerogenic substances (dioxins) as well as cadmium, which is taken in in high amounts from the smoke and damages kidneys and bones (osteoporosis). Then there is especially formaldehyde, which causes strong objective damage to the passive smoker with amalgam. Nicotine allergy is proven by a patch test. The passive smoker ingests much more toxins than the active one, where toxins are destroyed by the heat of the cigarette.

After only 20 minutes of passive smoking, urine analysis shows potentially dangerous levels of the dissimilation products formic acid and methanol (see Ch. 2.2.6.1 Formaldehyde). High formic acid levels damage the immune system, while a high methanol count damages the nerve system. Our chemical society, though, does not protect the sick or the young from these toxins.

Tobacco is treated with mercury-containing preservatives. Amalgam patients that continue to smoke surely do not deserve treatment.

3.2.1.11 Pentachlorophenol

This substance harms the energy intake in every cell by hindering the process of oxidative phosphorylation, thereby affecting energy production - "the engine runs at full speed, with a broken transmission". PCP is contaminated with dioxins. This means that the houses which were painted with PCP-containing wood preservatives became dioxin sites! PCP causes hormone and nerve disorders, as well as Cancer. Prohibited in Germany since 1979. Proof by analysis of swept house dust, acute **in whole blood and** chronically by patch-test.

3.2.1.12 Pyrethroids

None of the chemicals that **are** meant to kill animals (insecticides, pesticides) belong in houses, over the long term, because the most minute traces cause harm to the sensitive human brain. Even today we are not able to detect many of these toxins in the blood, some not even in floor dust, still they affect our organism (i.e. pyrethroids). Pyrethroids damage the brain and cause olfactory hypersensitivity, that is, a neuro-allergy against environmental chemicals. Proof by long-term patch test (see 4.3.1).

3.2.1.12 . Environmental Toxins

We would most likely never suffer so much damage from amalgam, if it were not for the various other long-term toxins to which we are exposed every day, that attack and weaken our detoxification System - thereby weakening the immune and nerve Systems dangerously. Of decisive importance is the amount of dioxins assimilated in the body.

3.2.1.14 Home Toxins

Some Chemical manufacturers have thought up new ways of raising the Profits of their industry - selling highly toxic and dirt cheap Chemical waste products in the form of wood preservatives, with which we paint our rooms, including the rooms of children, in highest concentrations.

Of course these poisons kill all insects and plants, while human fatalities, as expected, were observed only after decades.

The first people to become seriously ill were the ones that also had little tolerance for amalgam; they showed metabolic disorders, especially the enzyme-damaging lack of zinc. **Proof by patch test (see 4.3.1).**

3.2.1.15 Dental Toxins

Metabolic disorders that are connected to environmental problems, are aggravated by amalgam, often in youth. Amalgam damages the gums and periodontium of all teeth. The first molars (the first permanent molars) are often the first teeth attacked by caries, as a result they are the ones receiving amalgam first also. These teeth are problematic in the Upper jaw because they have triple roots. These roots are the first to die under the poison's influence,

3.2.1.16 Other Poisons

There are countless other poisons (food, clothing) which increase the effect of amalgam. Proof by **patch** test.

An amalgam patient who has ingested his poison for more than 15 years, will never recover unless he identifies all the important toxin sources together and eliminates them. Official authorities will only deal

with toxin sources that everyone recognizes and knows and which are not too costly to clean up.

SUMMARY

Group	Effects
Chrome	Allergen, immune poison, triggers autoimmune diseases
Dioxins	Strongest known immune poison and nerve poison
Formaldehyde	Used for root canal treatments along with antibiotics, cortisone, etc.; is assimilated irreversibly by jawbones, strong nerve poison, cancerogenic, inflammation causing, causes intolerance for synthetic materials
Gold	Allergen, triggers autoimmune diseases, anchors amalgam for life
Indium	Allergen, immune toxin, triggers autoimmune diseases
Ceramics	Insufficiently sintered ceramics release aluminium; allergy
Lindane	Affects potassium-sodium-magnesium assimilating enzymes in 108 locations of each cell, nerve poison, dioxin-contaminated
Metal ceramics	Most contain palladium; release aluminium, danger of Alzheimer's disease, trigger autoimmune diseases, strong immune toxin
Nickel	Strong allergen, nerve poison, triggers autoimmune diseases
Palladium	From catalytic Converters, strongest immune poison, allergen, triggers autoimmune diseases
Passive smoking	The worse the poison-related brain damage is, the stronger the-for example - sensitivity when passively smoking
Pentachlorophenol	Harms oxydative phosphorylation and so the energy intake, dioxin contaminated (floor dust!)
Platinum	Allergen, immune poison, triggers autoimmune diseases
Pyrethroids	Harm the brain, cause "multiple chemical Syndrome" strong allergen
Environmental toxins	The amalgam-damaged organism often reacts with allergies to them

3.2.2.3 Electromagnetic Fields

Electromagnetic radiation is emitted by monitors, Computers, mobile phones, high voltage wires, alarm clocks and other electric appliances. Electromagnetic sources cause a release of amalgam particles and ionize them. If metal crowns are also present - especially ones containing palladium - , they will cause electrosensitivity.

If an electrochemical process, caused by the proximity of one or several metal alloys to amalgam fillings - next or opposite - is already established, the disintegration process under the electromagnetic influence is multiplied manifold. The effect of metal-deposit induced foci on the organism is also increased.

3.3 Injurious Mechanisms

The released mercury is breathed in and reaches the brain via the nose the sinuses and the olfactory nerve - affecting especially the extremely poison-sensitive pituitary gland - or it enters the blood via the lungs with their huge surface of 400 sq.m. . Part of the mercury is swallowed and transformed into the 100 times more toxic organic mercury by the common intestinal bacteria.

A further part of the mercury is assimilated by the body through the dental gums, canals and roots and the jawbones, and distributed throughout the whole body. Some organs accumulate mercury more than others, in the following descending concentration :

- mucous membrane of the mouth
- dental roots
- tumors (cancer)
- cysts
- warts
- acne pimples
- liver
- specific brain areas
- nerves
- kidneys
- thyroid gland
- ovaries
- testes
- pancreas
- intestinal mucosa
- eyes
- inner ear
- muscles
- gallstones, and others

Mercury is constantly being converted from the anorganic to its organic State. Organic mercury is cancerogenic. Amalgam in a dental cavity affects all the teeth and their roots via the periodontium, and can cause parodontosis.

The way in which the toxin is fixed in the cells is genetically determined.

The varying symptom pattern is determined by the great variety of points of attack. Many points of attack are regarded as independent diseases (Alzheimer's disease, schizophrenia, etc.).

The specific action of mercury in an individual
is determined by his genetic make-up.

3.3.1 Attack Points Of Mercury In The Cell

Mercury blocks the nerve metabolism in more than 60 locations in each cell by attaching itself to the sulphur-oxygen-group of the coenzyme-A-ferment :

Hg - SH - coenzyme A

This enzyme blockade affects the following metabolisms :

- | | | |
|-----------|------------------------|-----------------|
| - brain | - fat | - trace element |
| - nerve | - carbohydrate | - formaldehyde |
| - protein | - vitamin (A, F, B 12) | |

{ For mercury there is no non-toxic amount.

3.3.2 Amalgam Allergy

Amalgam components like mercury and tin are allergens of the latent type. An amalgam allergy can be proven only in long-term testing. An amalgam allergy is a serious disorder in the immune System, which unfolds when the poison has already done its damage in the whole cellular System. When the allergy becomes evident, the allergen is already assimilated in all body cells and distributed almost equally throughout the body. It is very tragic when the victim realizes after years or decades that a poison has made him sick, and then wishes to remove the poison completely - which, of course, has become impossible at this point.

Local Symptoms like contact Stomatitis, gingivitis, lichen ruber of the oral mucous membrane, constantly relapsing aphthoid alterations or a therapy resistant perioral dermatitis are only the most obvious indications of the whole clinical picture, if they appear in connection, timewise, to the amalgam installation.

A nickel allergy is an indication of an amalgam allergy, since every patient with an amalgam allergy also shows a nickel allergy.

80 % of the amalgam allergy patients also suffer from a gold / palladium allergy if they also had a gold crown.

3.3.3 Autoimmune Diseases

Any long-existing allergy against an allergen that has been accumulated in the organism can be the cause of an autoimmune disease. In 400 proven cases of autoimmune disorder, in 94 % the cause was amalgam (2 % were caused by gold, 2 % by palladium, 1 % by pentachlorophenol and 1 % by solvents).

This makes amalgam the single most important cause of autoimmune disorders. 5 % of the German people die of this cause. All major diseases of affluence take their root in an autoimmune disorder.

Autoimmune diseases are intoxications by depot toxins like amalgam and gold, which - like cell allergies - lead to the destruction of cells, organs or the whole organism, according to the all-or-nothing rule. Autoimmunity means the reactivity of the immune system against structures in its own organism (auto-antigens), therefore, against "itself"

The organism burns itself out from inside. Without genuine cause removal, autoimmune disorders are fatal. Cortisone can sometimes extend life for a while and relieves symptoms in the beginning, but it boosts not only the original cause of the disease but also the immunological weakness against the self-destructive immune complexes. The most tragic cases are the ones where the patients are sent off to psychotherapy - "you'll feel better"- or are subjected to mutilating surgery - for example the removal of intestines in a case of Colitis - instead of a correct cause removal. After removal of the poison a symptomatic therapy can include specific similar antibodies like T-lymphocytes, which help the auto-antibody to produce B-cells, to bind the auto-antibodies produced by the T-lymphocytes in complexes. The prerequisite, though, is always the removal of the cause, which, for all diseases of affluence means the removal of all dental metals (under protection!) and all toxin foci (pus) from the mouth.

Autoimmune Diseases Couused By Amalgam

Addison's disease
 Allergies
 Alveolitis
 Alzheimer's disease
 ALS (amyotrophic lateral sclerosis, or Lou Gehrig's disease)
 Anemia, hemolytic
 Anemia, pernicious
 Anorexia
 Asthma

 Bechterew*s disease
 Blood coagulation disorders
 Cancer (breast,colon, pancreas, stomach, lung)
 Celiac disease
 Chronic-fatigue-Syndrome
 Churg-Strauss-Syndrome
 Cerebellar atrophy
 Cerebral atrophy from birth
 Cirrhosis, cryptogenic, of liver
 Colitis ulcerosa
 CREST-Syndrome
 Crohn's disease

 Dermatomyositis
 Diabetes mellitus
 Duchenne-Aran disease (progressive spinal muscular atrophy)

 Eclampsia
 Endocarditis

 Feer-Syndrome
 Felty's Syndrome
 Fibromyalgia

 Gastric mucosa atrophy
 Gilbert's Syndrome
 Goodpasture's Syndrome (renal insufficiency)
 Grove's disease
 Guillan-Barre-syndrome

 Hairloss, total (Alopecia totalis, areata)
 Hashimoto's thyroiditis (HT)
 Hepatitis, chronic and viral
 Heart complaints
 Hodgkin's disease
 Hearing weakness
 Hydrocephalus from birth

 Infertility

 Kleine-Levin- Syndrome

 Liver, biliary cirrhosis
 Leukemia (acute myelogenous, lymphatic)
 Leukopenia
 Lupus erythematosus

 Menopause, early
 Microinfarctions
 Killer-Fischer-syndrome
 Mediterranean acne
 Mononucleosis

Autoimmune Diseases Caused By Amalgam (continued)

Motoneuron-Syndrome
 Multifocal motoric neuropathy
 Multiple Chemical Syndrome (MCS)
 Multiple Sclerosis (MS)
 Muscular atrophies
 Myasthenia gravis
 Myocarditis
 Myxedema, primary

 Narcolepsy
 Neurodermatitis
 Nephritis (kidney infections)

 Pemphigoid
 Pemphigus vulgaris
 Pericarditis
 Polyarthrititis
 Pulmonary fibrosis
 Psoriasis

 Raynaud's disease
 Rheumatoid arthritis
 Rheumatic fever
 Retinal detachment

 Schizophrenie
 Sharp-Syndrome
 Scleroderma
 Sjögren's Syndrome
 Sprue (diarrhea)
 Stiff-man Syndrome
 Sympathetic eye disease

 Thrombocytopenia
 Thrombocytosis
 Thyrotoxicosis
 Tourette's Syndrome

 Ureitis, phagocytic

 Vasculitis (heart and brain infaretions)
 Visual disorders
 Von Willebrand's disease

 Wegener's granulomatosis
 Wilms' tumor
 Wilson's disease

3.4 Symptoms ("Daunderer-Syndrome")

Neurological Symptoms

aggressiveness
anti-social behavior
awareness, lack of a. for the essential

back pain
bedwetting
blindness
blushing, easily
body pains
bone pains
brain disease

cancerophobia
cardiac disrhythmia
cardiac sensations
cardioneurosis
choking, sense of
choleric behavior
consciousness impaired
crib death (SIDS)
crying, tendency for

depression
disequilibrium
disinterest
disk damage
double images
drug addiction
dyspnea
dystonia, vegetative

eating disorders
energy, lack of
epileptic cramps
exhaustion, easily

facial paralysis
facial twitches
fatigue, chronic
fear of people
fear of the new
fear of suffocation
frosted glass, feeling as if behind

hallucinosi
handwriting, shaky
headaches
hearing disorders
hearing loss, acute
hiccups
hot flushes
hypertension
hyperactivity
hypersexuality
hyperventilation tetany
hypesthesia
hysteria

Neurological Symptoms , continued

impotence
 indecision
 inferiority, sense of
 irritability
 ischialgia

joint pains

lack of drive
 limb pains

megalomania
 memory disorders
 memory loss
 meniscus pain
 migraines
 moods, labile
 mouth pain
 muscular weakness / cramps
 muscle twitches
 multiple sclerosis

neurasthenie
 neurosis
 nervousness

numbness



obsession with the environment
 olfactory disorder

pain
 panic, fits of
 paranoia
 paralysis
 polyneuropathy
 pronunciation unclear

rage, fits of
 reactions, slowed

salivation in sleep
 schizophrenia
 sexual excitability changed
 shouting, fits of
 shyness
 sleep disorders
 sleeplessness

(standing beside oneself, feeling of
 smoking
 startled, easily
 stomach pains
 stuttering
 suicidal tendency
 swallowing problems

tendons, painful
 tension, inner
 thought disorder, temporal / spatial
 tics
 tooth grinding

Neurological Symptoms, continued

torticollis (wryneck)
tremors, intensified with intention
trigeminal neuralgia

unrest, inner

vertigo
visual disorders

weakness, sense of

Immunological Symptoms

acne
anemia
angiospasms
anorexia
allergies
appetite, lack of
aphthous ulcers
asthma

blisters, oral
blood circulation disorders
blood coagulation disorders
blood pressure high / low
blood sugar, high (hyperglycaemia)
bronchitis

cancer
childlessness
cholesterol, high level
cold feet
coldness, feeling of
common cold, persistent
constipation
contact stomatitis

dermatitis, perioral
diarrhea
dyspnea (respiratory distress)

eating disorders
eczema
electrosensitivity

formaldehyde allergy
fungal infections

gingivitis
gums, blue-purplish color

Immunological Symptoms , continued

hair loss

hormonal disorders

hydrocephalus

infections, tendency for

infertility

intestinal disorders

intestinal inflammation

immunal weakness

iron, lack of

irritation cough

ischialgia

itch

joint pains

kidney damage

liver damage

lichen disease

lichen ruber of oral mucous membrane

meteorism (gas)

menstrual disorders

metallic taste

myocarditis

myoma

neurodermatitis

oral mucuous membrane copper colored

parodontosis

pharyngeal pain

pituitary tumor

psoriasis

rheumatism

sinusitis, paranasal

teeth, deterioration of

ulcers

urinary urgency, constant

urine, much / little

viral infections

weight loss

zinc deficiency

3.5 Amalgam Career

Newborn child, first months (from mother)	Hydrocephalus, blindness, deafness, neurodermatitis, restlessness, crying, not sucking well, underweight, overextendable joints, sudden infant death by suffocation.
Kindergarten age	Umbilical colics, bedwetting, whining, unsocial, loner, "hysterical", not relating, angry, disinterested.
School age	Learning difficulties, asthma, weak bladder, visual disorders, muscle weakness, addiction to social drugs (smoking, alcohol), anemia, hyperkinetic syndrome (Feer) .
Around age 16	Schizophrenia (hebephrenia), suicidal tendency, anorexia, depression, drug addiction, menstrual disorders, hypersexuality, antisocial, acne, lack of drive.
Around age 20	Multiple sclerosis, migraine, joint pains, abdominal pains, bladder pain, nephrosis, memory problems, pain during physical exercise, racing heart, fear, aggressiveness, burning eyes, inflammation of visual nerve, allergies.
Around age 30	Rheumatism, colitis ulcerosa, Crohn's disease, tremors, vertigo, infertility, high cholesterol level, myocarditis, muscle weakness, stomach ulcers, cold shivers, ovarian cysts, uterine myoma, fungal infections, circulatory disorder.
Around age 40	Diabetes, electrosensitivity, backaches, low resistance to infection, multiple chemical syndrome, formaldehyde metabolism disorder, blood coagulation disorders, Bechterew's disease, ALS, stamina deterioration, acute hearing loss, sleep disorders, hair loss, psoriasis, eczema, lumbago, paralysis, numbness, nerve pain (trigeminal), partner problems (divorce).

Around age 55	Osteoporosis, cataract, eye retina detachment, electrosensitivity, kidney disease, hypertension, liver disease, tinnitus, oral mucous membrane disorders, heart rhythm disorders, tumors.
Around age 60	Stroke, infarct, cancer, infirmity, cachexia, Alzheimer's disease.

Typical for amalgam is the great variety of symptoms - depending on the length of exposure.

90 % of all diseases are co-influenced or caused by amalgam. Doctors, psychologists and social workers earn money from the effects of amalgam, the taxpayers and health insurance takers pay the enormous bill.

3.6 Dental Foci

Amalgam is an antibiotic. When an antibiotic affects a locale over a long period of time, dangerous and resistant bacteria and fungi grow. These then turn the less dangerous anorganic mercury into the highly toxic organic mercury, which accumulates in the brain.

This locale, where bacteria and viruses grow around the periodontium and the dental root, is called a "dental focus". Without extreme stress, this focus remains isolated and damages specific organs by irritating the nerve system ^(trigeminus) via the medulla oblongata, a junction point located in the head. Basically, all the nerves are affected, but - as the Chinese discovered more than 3000 years ago - specific organs / organ systems that are related to specific teeth, are affected more frequently. This scheme is called the "dental focus diagram". Each specific organ damage is a direct result of the amalgam poisoning and is therefore a part of the amalgam disease. Like in a dictionary, one can see in this diagram, which organ system was damaged by the amalgam accumulation, ie, where an autoimmune disorder can be expected to develop.

Dental foci are metabolism disorders caused by local as well as environmental toxins. A focus can be detected by injecting a local anesthetic beneath a tooth that is revealed as a dental focus on the panoramic x-ray - meaning that it shows inflammation caused by bacteria, fungi or toxins. After about 20 minutes, the patient suddenly senses pain in the area affected by the focus (ie knee, spine, eye, etc. -

Typical for a focus are: dead teeth, deep amalgam (close to the root), amalgam under gold, amalgam fragments in the jawbone or under the root, but also bacteria and toxins that were enclosed in the jawbone wound after tooth extraction. This is the most common cause for chronic zinc deficiency, rheumatism and heart trouble. One-sided foci lead to one-sided brain damage with related physical deficiency on the opposite side of the body. .

Inflammation stage :

1. Hidden - no symptoms
2. Manifest - acute organ damage
3. Irreversible - permanent organ damage

Diagnosis :

- A. X-ray, magnetic resonance imaging, function analysis, neural diagnosis.
- B. Swab for bacteria and fungi
- C. Toxin diagnosis (multi element analysis)

Adrenal gland	41 42 31 32
Allergies.....	16 26 36 46
ALS	18 28 38 48 11 12 21 22 31
Arteries, veins	36 37 46 47
Asthma	16 26
Brain	11 12 21 22 31 32 41 42
Brain focus	11 12 21 22 31 32 41 42
Breast	16 17 26 27 34 35 44 45
Cancer	All , especially 36 and 46
Central nervous system	18 28 38 48 11 12 31 41
Colitis	36 46
Diabetes mellitus	14 24 34 44
Ears	18 28 38 48

Illness	Possible Dental Focus
Elbows:	18 28 36 37 38 46 47 48
Energy	38 48
Feet, Toes	14 15 24 25 46 47 36 37 31 32
Gallbladder	13 23 33 43
Glands	14 24
Hands (outside)	36 37 46 47 14 15 24 25
Hands (inside).	18 28 38 48
Heart	18 28 38 48
Hips	13 23 33 43
Hormones	14 24 34 44
Immune system	16 17 26 27 36 37 46 47
Intestines, large / small	18 28 36 37 38 46 47 48 14 15 24 25
Knee (back).	31 32 33 41 42 43
Knee (front)	16 17 26 27 34 35 44 45
Kidney	11 12 21 22
Liver	13 23 33 43
Lower back	31 32 41 42
Lung	14 15 24 25 46 47 36 37
Lymph vessels	34 35 44 45
Multiple sclerosis	18 28 38 48 11 12 21 22
Parathyroid gland	16 17 26 27
Pancreas.	14 24 34 44
Pituitary gland, posterior lobe..	13 23
Pituitary gland, anterior lobe..	18 28
Psyche	18 28 38 48
Rheumatoid arthritis	All
Shoulder.	15 25 35 45
Sex glands	43 44 33 34
Sinus, frontal	11 12 14 15 21 22 24 25
Sinus, paranasal	14 15 24 25
Sinus, maxillary *	16 17 26 27 34 35 44 45
Spine	11 18 21 28 31 38 41 48
Spleen	26 27 34 35
Stomach	16 17 26 27 34 35 44 45
Spine, thoracic / lumbar	18 28 34 35 44 45
Vertebra and joints	All
* Sinus, parafrontal	36 37 46 47

Sensory
organs

Hearing

Organs

CNS Heart
Small in-
testine r.
Psyche

Maxillary
sinus
Breast r.
Stomach r.
Immune system

Frontal
sinus
Lung r.
Lg. intest-
tine r.
Paranasal
sinus

Eye

Liver r.
Gall-
bladder

Vertebrae

TS, LS

TS, CS

TS

TS

TS

TS

TS

TS

TS

TS

TS

TS

TS

TS

TS

TS

TS

TS

TS

TS

TS

TS

TS

TS

TS

TS

TS

Vertebrae

TS, LS

TS, CS

TS

TS

TS

TS

TS

TS

TS

TS

TS

TS

TS

TS

TS

TS

TS

TS

TS

TS

TS

TS

TS

TS

TS

TS

TS

Vertebrae

TS, LS

TS, CS

TS

TS

TS

TS

TS

TS

TS

TS

TS

TS

TS

TS

TS

TS

TS

TS

TS

TS

TS

TS

TS

TS

TS

TS

TS

Vertebrae

TS, LS

TS, CS

TS

TS

TS

TS

TS

TS

TS

TS

TS

TS

TS

TS

TS

TS

TS

TS

TS

TS

TS

TS

TS

TS

TS

TS

TS

Vertebrae

TS, LS

TS, CS

TS

TS

TS

TS

TS

TS

TS

TS

TS

TS

TS

TS

TS

TS

TS

TS

TS

TS

TS

TS

TS

TS

TS

TS

TS

Vertebrae

TS, LS

TS, CS

TS

TS

TS

TS

TS

TS

TS

TS

TS

TS

TS

TS

TS

TS

TS

TS

TS

TS

TS

TS

TS

TS

TS

TS

TS

Vertebrae

TS, LS

TS, CS

TS

TS

TS

TS

TS

TS

TS

TS

TS

TS

TS

TS

TS

TS

TS

TS

TS

TS

TS

TS

TS

TS

TS

TS

TS

Vertebrae

TS, LS

TS, CS

TS

TS

TS

TS

TS

TS

TS

TS

TS

TS

TS

TS

TS

TS

TS

TS

TS

TS

TS

TS

TS

TS

TS

TS

TS

Vertebrae

TS, LS

TS, CS

TS

TS

TS

TS

TS

TS

TS

TS

TS

TS

TS

TS

TS

TS

TS

TS

TS

TS

TS

TS

TS

TS

TS

TS

TS

Vertebrae

TS, LS

TS, CS

TS

TS

TS

TS

TS

TS

TS

TS

TS

TS

TS

TS

TS

TS

TS

TS

TS

TS

TS

TS

TS

TS

TS

TS

TS

Vertebrae

TS, LS

TS, CS

TS

TS

TS

TS

TS

TS

TS

TS

TS

TS

TS

TS

TS

TS

TS

TS

TS

TS

TS

TS

TS

TS

TS

TS

TS

Vertebrae

TS, LS

TS, CS

Treatment : In the case of a dental focus, a significant improvement of the patient's condition can be achieved only by technically correct tooth extraction and surgical cleansing of the wound - after the third day the affected organs can cause strong complaints, which then improve slowly. If a relapse in the affected organs occurs and the symptoms become unbearable, the old foci must be reopened surgically and cleaned again. This should be done repeatedly in 6-month-intervals.

Focus Irritation

In order to identify organ damage that was caused by jawbone inflammation, the dental root that is seen on the x-ray as changed, can be subjected to an anaesthetic injected in proximity to it (without vasoconstrictive drugs or preservatives) ; this is the so-called "neural therapy".

If the inflamed tooth is indeed the cause of the damage in the endorgan, then the inflamed endorgan will cause pain after anaesthesia of the dental focus. If there is no significant improvement in the endorgan after three injections in one-week intervals, the focus must

be purged; that is, the tooth extracted and the tooth socket routed with a drill and a gauze strip with antibiotic ^{eyedrops} laid inside, and renewed periodically, untill the bone heals and the wound closes toward the oral cavity. Provisionally, the focus can be massaged from the outside (ie tooth 48 in case of heart trouble).

***** DENTAL FOCUS DIAGRAM (see separate pages) *****

Where a bone metabolism disorder is present, all other ingested poisons (mostly via the respiratory system) are also assimilated and reinforce the amalgam sickness. An amalgam patient will not regain health without avoiding these additional factors.

3.7 Metabolism Anomaly

There is a genetically caused anomaly in connection to amalgam, where the sick person does not excrete ^{the} poison by the usual way of the kidneys, but mainly via the liver. In this case, mercury is excreted by the gall bladder into the intestines.

This can either bring about a colitis, through local irritation, or a psychosis, through accumulation of organic metals in the brain. It is possible to determine the mercury excretion rate in the third stool, after swallowing an antidote.

3.8 Degree of Poisoning

The severity of an amalgam poisoning does not depend on the amount of such fillings present at the time, or on hidden amalgam in the form of root filling material or bases under gold crowns. It depends on the location and the amount of the amalgam accumulated in the body, and especially on the degree of the allergy against the accumulated poisons.

It is not the amount of fillings, but rather the toxin depots in the organism and the metabolism disorders which determine the extent of a poisoning.

The tendency for toxin accumulation, on the other hand, depends on all the above listed factors.

The locality of the toxin depots determines the nature of the symptoms.

3.9 Advantages of Amalgam

Besides its unbeatable advantage in being the cheapest dental filling material, which can be laid durably even by lay persons (this is its origin), it has other invaluable properties :

The victim often realizes his deteriorating health early on and instinctively rejects other social drugs and life-threatening kinds of sport.

When strangers explain the problem to him, the poison victim is often able to improve his life quality decidedly - with other environmental toxins this is not so. Help by laypersons produces a feeling of thankfulness which other people lack.

Very small, but regular doses are more dangerous than one single large dose.

The realization, that the effects of chronic poisoning cause auto-immune diseases (allergies), helps the amalgam victims to better get along with modern life than healthy people do.

Amalgam brings great personal benefits for the medical professionals.

The amalgam patient causes much less damage to the environment than a healthy person, because he works less and is less active in his leisure time.

The attitude of officials towards amalgam is a good indication of their knowledge about the chronic toxic effects of smoking, drugs, automobile emissions, deforestation due to pollution, formaldehyde, home toxins, wood preservatives, dental toxins, etc..

Amalgam in your own body is the best ecological lesson.

Ideas, followed by action, solve problems.

4 CLINICAL PROOF

Diagnostics By Specialists In Cases Of Amalgam Poisoning

Physician	Symptom	Diagnosis / Therapy
Cardiologist	Heart rhythm disorders Infarction Myocarditis	Focus localization : 38,37,48 (47) Autoimmune tests
Dermatologist	Allergies Hair loss Acne (amalgam-acne) Oral mucous membrane disorders Psoriasis Eczema	Patch tests for all dental materials (7 days) Autoimmune tests DMPS-test
Gastroenterologist	Ulcers Colitis ulcerosa Crohn's disease Liver disease	Autoimmune tests DMPS-test Test excision for Hg
General Practitioner	Stamina decline Sleep disorders Depression Cholesterol level raised	Oral examination Autoimmune tests DMPS-test
Gynecologist	Infertility Ovarian cysts Uterine myoma Menstrual disorders	Autoimmune tests DMPS-test
Hematologist	Anemia	Autoimmune tests DMPS-test
Immunologist	Low resistance to infections Shivering Fungal infection	DMPS-test Autoimmune tests
Neurologist	Lumbago Paralysis Nerve pains (trigeminus) MS Alzheimer's Tendon pain Tremors	DMPS-test Autoimmune tests MRI head
Nephrologist	Kidney disease Bladder disease Hypertension	Al-microglobuline DMPS-test Focus localization

Physician	Symptom	Diagnosis/Therapy
Oncologist	Tumor	Tumor for Hg Autoimmune tests Exposure stop
Ophthalmologist	Visual deficiency Conjunctivitis Optic nerve inflammation	Focus localization: eye tooth 13, 23, (33,43) Allergy tests DMPS-test Autoimmune test
Otorhinolaryngologist	Hearing disorders Vertigo Acute hearing loss Tinnitus	Maternal amalgam Teeth 7,8 with amalgam Autoimmune tests DMPS-test
Paediatrician	Birth defects (hydrocephalus) Weight loss Hyperkinetic syndrome Psoriasis Anemia	DMPS-test (stool) MRI of head
Pathologist	Sudden infant death Suicides	Breathing center for Hg Hg in specific brain areas
Psychiatrist	Depression Schizophrenia Nervousness Aggressiveness Fear Sleeplessness Lack of drive Electrosensitivity	DMPS -test, with stool analysis MRI of head Autoimmune tests
Sports specialist	Performance loss Tendonitis Myocarditis	DMPS-test Autoimmune tests

* * * * *

Proof is the prerequisite for correct treatment.

We have proof for a poisoning, when these are proven :
Poison - Poison intake - Toxic effect

The consulting physician or dentist can judge a case of amalgam poisoning only when ALL these proofs are in evidence. This is especially important for legal procedures.

-and
Laboratory analysis ^Δmuch of it - is the basis for
competence in this field.

4.1 Proving the Toxin

4.1.1 Chewing-gum Test

Collect the saliva while chewing gum or brushing teeth for 10 minutes in the morning (no chewing of anything for two hours before). This saliva provides the proof for the amount of poison released from the dental repair material, by laboratory analysis. This way we can determine whether ^{imported} ~~cheap~~ ^Δamalgam was used, containing lead or cadmium, or highly allergenic amalgam from Germany, containing palladium, indium or zinc.

Old and corroded amalgam fillings can set free huge amounts of toxins, also amalgam fillings in conjunction with other metal alloys in the mouth (nickel bridges or palladium crowns).

Severe poisoning can occur if the combined concentration of mercury and tin is above 50 µg/liter.

According to the dentists there is no definite limit at all where the intoxication should be stopped. Up to 4 million µg mercury per liter saliva have been measured in poisoned patients. Drinking water could not be sold above a mercury content of 1 µg/l, although it does not release mercury vapors at night, like amalgam fillings.

Apart from mercury we measure tin, silver, copper as well as lead, cadmium, palladium etc. content by MEA (multi element analysis).

The higher the readings in a chewing-gum test are, the higher the toxin accumulation in the organs (see DMPS test).

Limit Values

There are no 'limits of toxicity' for ultra-toxins like mercury and tin, which always cause damage. The extent of the damage depends on the fragility of the organism. Therefore the sick and the young have to preventively avoid all exposure to toxins; one needs to act as with asbestos, where all contact with the poison must be strictly avoided in the disposal process. The severest care needs to be applied with allergy and autoimmune patients - here the limit value is zero.

There is no harmless amount for amalgam,
therefore there is also no limit value.

4.2 Proof of Poison Assimilation

4.2.1 Advice

Experienced physicians can use **x-rays** for a quick assessment of the results of a poisoning. The prerequisite for applying these techniques, though, is experience with at least 500 cases of poisoning, the course of the sickness and its laboratory readings. In this way, the patient can often be spared lengthy examinations and operations.

OPT and MRI serve the experienced physician for orientation in diagnosis.

4.2.1.1 Orthopantomography (OPT)

Also called panoramic radiograph or panoramic x-ray.

The radiation level of an OPT is, at the most, about one hundredth of a single-tooth x-ray, where the radiation passes through the body from above without protection, constantly reflecting itself on the sternum and spinal column, with the possibility of causing considerable damage to the gonads. This means that a standard single-tooth x-ray causes 100 times the radiation exposure of an OPT ! In addition to this, the single-tooth x-rays are completely useless for toxicological diagnosis because the area under the root is missing.

A healthy bone shows a regular structure in the OPT, without any white or black spots.

We judge the following :
Periodontium, tooth neck, blood vessels and nerve canals, bone density, mandibular joint, mandibular floor, mucous membranes of the paranasal sinuses, jawbone adenoids, lymphnodes in the jawbone corner, foreign matter in the bone, metallic edges and accumulations of other metabolic toxins.

The jawbone is our filter and depot organ for all breathed-in and jawbone-implanted poisons. An experienced therapist can identify all the major long-term toxins in the special, soft and low-radiation OPT and can tell how the organism reacts to these foreign substances.

Identifiable in an OPT are :

Metal foci, pesticides, solvents, PCP, formaldehyde in the jawbone,

dead teeth (ie root canal treated), wisdom teeth with foci (ie grown into a nerve canal).

Localisation in Jawbone	Toxin	Appearance in OPT
rising jawbone corner	formaldehyde (from passive or active smoking) solvents, PCP, pesticides	dot-shaped, nerve canal edges are surrounded by a bright band black lakes
beneath the root tips	metals osteomyelitis formaldehyde solvents, PCP, pesticides	bright, garland-shaped foci, between the roots disc-shaped bright, dot- or comma-shaped dark areas black lakes (under 6 tooth)
jawbone floor	amalgam metals (palladium, gold)	bright, mist-like, soft re- flection bright, weal-like, hard reflec- tion

* * * * *

We differentiate among the following focal areas in the jawbone :

Brain, eyes, ears, nerves, heart, gastro-intestinal tract, chest, rheumatism, hormones, diabetes, allergies, etc..

The diagnosed abnormalities are indications which need to be confirmed by other diagnostic techniques (laboratory analysis of dental root for metals, SPECT for solvents etc).

4.2.1.2 MRI Of Brain

Magnetic Resonance Imaging is not an x-ray; it utilizes a magnetic field - the examination does not require a contrast medium (gadolinium). The discomfort related to the magnetic field increases ⁱⁿ proportion _Δ to the amount of metal in the patient's mouth. This can take the form of claustrophobia - old machines required the patient to enter up to

the chest into a tight tube. Today we have open machines.

Especially the patients with palladium in their mouths suffer from electrosensitivity caused by the strong magnetic field.

In an MRI the experienced physician can identify deposits and the brain's reaction to the foreign substances in the jawbone and sinuses, as well as toxin-related brain atrophies, signs of inflammation, MS, birth defects, abnormalities of the eye, the inner ear, the cerebellum, the breathing center and others.

An analysis of the results concerning the toxins can be made only by the clinician in connection to the other toxicological proofs and processes. The radiologist can only identify the morphological changes, ie enlarged Virchow-Robin-spaces, but the cause remains hidden to him. The suspected toxins (see OPT) can be confirmed by MR Imaging.

FOCI

Dental alveoli

Amalgam that surrounds the roots has a metallicly dense appearance in the x-ray. Also all other metals, ie lead, bismuth, aluminium and others appear similar in their deposits.

A surgically removed depot can be analyzed for an exact toxicological reading of the depot metals.

Maxillary sinus

The same metals can be accumulated in the mucous membrane as in the tooth sockets. While a healthy membrane shows up black on the image, a metal-rich membrane has a light to intensive white appearance. If a depot is suspected, a tissue sample can be sent to the laboratory for metal analysis.

Pituitary gland

Inhaled metals are accumulated in the anterior lobe (ie dentists), while dental metals accumulate in the posterior lobe (amalgam, palladium).

Brain stem

All inhaled poisons accumulate in the brain stem. Foci in this area cause Multiple Chemical Syndrome; that is, an intolerance towards all inhaled toxins and allergy against all medications (vitamins, psychotherapeutic drugs). In the breathing center one can find toxin foci caused by amalgam, which lead to sleep apnea.

Cerebellum

Inhaled amalgam forms metal deposits on the edges of the cerebellum, which disrupt passages and can then lead to difficulties with walking (wheelchair!) which are centrally caused. Metal deposits in this area can also cause cerebellar atrophy.

Cerebrum

Metal deposits in the cerebrum can cause cerebral atrophy.

Lateral ventricles

Every amalgam carrier and every child of an amalgam carrying mother shows gritty metal deposits, the size of pinheads, which are called UBOs (unknown bright objects; white matter lesions) .

When patients with many such toxin deposits in their brain had their amalgam removed without triple protection or received palladium as replacement, we found large spots (MS), with correlating nerve system disorders - sometimes wheelchair dependency - in the control tomography in more than 200 cases. On the other hand, a correct amalgam removal with ensuing detoxification let all indications of UBOs disappear over some years.

In the metal mode, amalgam depots are differentiated from vessel (microembolism) and tissue (fat) disorders.

Pallidum

Foci in the brain core on the right side of the brain cause a mania, on the left side a depression. Foci here are often found in cases of MS. Only rarely are the foci equally strong on both sides (manic depression), most of the time they are more developed on the left, very seldom only on the right side. After every amalgam removal we observe changes in the patient.

4.2.2 Proof

4.2.2.1 DMPS-Test

DMPS is the salt of the sulfuric liver, which was recommended by Hahnemann, the father of homeopathy. It is the only gentle antidote for amalgam poisoning, which also flushes out co-components like tin, lead and cadmium from the body. The amount of excreted poison measured in the urine, after a single trial dosis of the antidote

constitutes a proof for the extent of the toxin accumulation in the body.

DMPS (Dimercapto-propanol-sulfate) is a sulfuric salt with which mercury bonds in the blood; it is a metal salt binder. In cases of chronic poisoning the first reaction to DMPS is a surge-like excretion of all poisons attached to ^{the} sulfur, by way of the kidneys and the intestines (also skin and lungs). First, then, the toxins are flushed out of the kidneys and liver. An ensuing "vacuum"-effect then drains the depot organs, especially the brain.

Particularly the brain detoxification often has an effect like opening a champagne bottle. When the blood is free of poison after DMPS, the redistribution of the poisons from the organs into the blood takes up to six weeks. After this time the highest toxin level is once again detectable in the blood, liver and kidneys.

The DMPS-injection, then, has proven itself especially well. As long as there are amalgam fillings in the mouth, though, the renewed absorption of poison into the organism is increased after each DMPS-injection; that is, the excretion increases continually. After each detoxification the mercury levels in urine and third stool must be measured.

Trade names

"Dimaval" capsules 100 mg, ampules 250 mg (manufacturer: Heyl, Berlin, Germany)

"Unithiol" ampules 500 mg (manufacturer: Oktober, St. Petersburg, Russia)

The Russian preparation is processed differently, which makes for a much weaker and less allergy prone effect.

Antidote	Injection mg/kg body weight (kidney detoxification)	Swallowed mg/kg b.w. (liver detox.)
DMPS	3.5	1.5 - 12
DMSA	-	1.5 - 12

Often, an improvement of the symptoms becomes noticeable only after several mobilisations.

If the symptoms persist and no poisons are excreted, the patient has to be checked for a metabolism disorder which can cause the mercury to be excreted only via the stool after an intravenous DMPS-injection.

4.2.2.1.1 Injection im / iv

Injections into the vein are especially suited for diagnostical purposes because absorption from the blood into the effect organs takes place within 10 minutes, after a further ten minutes the kidney will excrete the main part of the poison, the liver after 20 minutes. If the injection is given into the muscle, transfer from there into the blood requires another 15 minutes. In urine specimens, the greatest poison amount is measurable about 45 minutes after injection into vein or muscle.

The part of the DMPS that is excreted via the liver into the gall, from there transports the amount of mercury into the stool which can be measured in the sample from the third stool onward. In dangerous cases, organic mercury can also be found there by analysis.

Since the injection causes the major part of the poison to be excreted via the kidneys, the extremely rare case of a severe kidney disorder (creatinine over 4.5 mg/g) necessitates a first mobilisation via the stool using DMPS capsules. Injection into the muscle brings a slower, longer, and therefore gentler excretion of the poisons. Here the analytical data is not as reliable, though, and the healing effect not as evident for the patient - who often will realize only through the antidote what effects mercury caused in his organism.

Newborn children can already receive a DMPS injection (1 ml = 50 mg into the muscle).

4.2.2.1.2 Creatinine

Creatinine as a conversion factor :

If a person drinks little, he will have much toxin and a high creatinine level in deeply yellow urine. If a patient drinks much, he will show few toxins in transparent urine. In order to be able to draw comparisons, we always also measure the creatinine level and calculate the toxins per one gram creatinine, that is, one divides the

toxin level by the creatinine reading. For the organism , of course, high poison levels in a concentrated urine are more damaging in the long run. Drinking much is always good when dealing with any kidney poison.

We examine the urine 45 to 60 minutes after the injection.

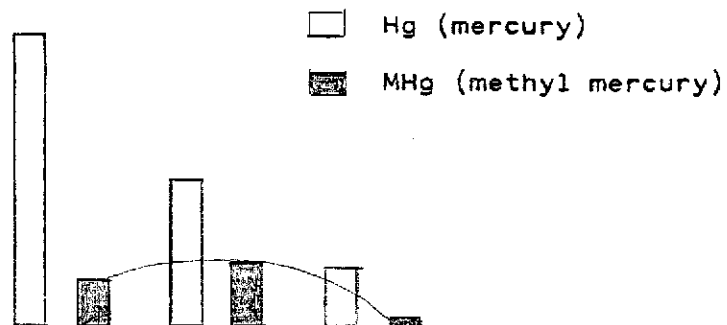
4.2.2.1.3 Organic Mercury

In a DMPS test the percentage of organic mercury (methyl mercury) gives us an indication of the severity of the caused organ damage. The percentage depends on the common transformation rate.

1. Normal findings

Normal ratio of methyl mercury in the total excreted mercury is 30 % .

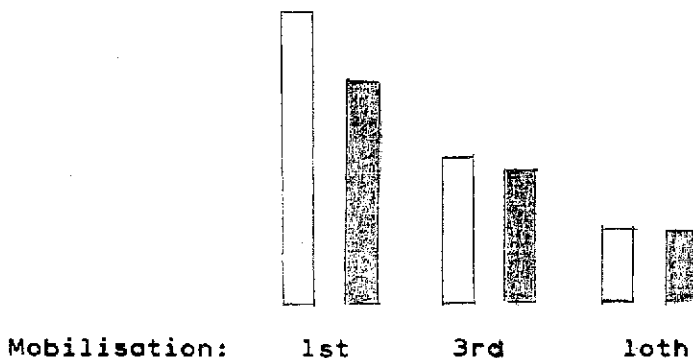
30 % organic mercury



First ... Third...Tenth mobilisation

2. Severe organ damage

A high percentage of organic mercury (over 60 %) is typical for severest nerve damage or cancer.



In these cases detoxification is very important. In the beginning preferably injections, later on capsules or DMSA-powder is possible.

4.2.2.1.4 DMPS-capsules

DMPS capsules are labelled only for acute mercury and arsenic poisoning, with a dosage of 3 capsules per day. For a case of amalgam poisoning, though, this dosage makes no sense, because here all the poison is accumulated in the organs and can only be drawn out very slowly. Patients have to be ^{advised} ~~be~~ explicitly before taking capsules.

Capsules are assimilated in an uncertain way via the intestinal tract and strongly increase the toxin excretion through the stool; in cases of inflammatory, poison-related intestinal disorders (colitis ulcerosa, Crohn's disease) this can lead to an unnecessary inflammatory episode.

An injection, which causes excretion mainly by way of the kidneys, would avoid this problem. About a third of the capsule content is assimilated by the blood, therefore the dosage needs to be triple that of an injection (10 mg instead of 3 mg/kg body weight), so as not to strengthen an allergy disposition by the low dosage. Treatment with capsules is much more expensive than with injections, because the assimilated amount of antidote determines the amount of excreted toxin, and one injection equals the assimilated antidote amount of 12 capsules.

On the other hand, in psychotic illnesses (schizophrenia), with metabolic disorders and mercury excretion via the stool that is too high, the repeated taking of a DMPS capsule has shown good results (2 to 3 times a week 100 mg). But this is an exception.

Allergies against DMPS :

Where an allergy against sulfur mercury (thiomersal, mercaptobenzo-thiazole) exists, there is also an allergy against DMPS and DMSA. Previous sulfur prescriptions or a catalytic converter in a car will boost this allergy. In case of a sulfur allergy no chemical detoxification is possible. Detoxification must then be done surgically. There are no effective alternatives.

A DMPS /DMSA allergy is easily identifiable through a patch test (seven days) or an LTT test.

Toxin Excretion after DMPS

The level of toxin excretion is relevant only for healthy people. For the sick (allergic) patient, a limit value of zero for all toxins is valid.

An alcoholic with liver cirrhosis can die of a very low alcohol level in his blood, even though the law in Germany allows people to drive cars with double that blood alcohol level. Limit values are valid only for healthy adults. If the mercury level in the urine after a DMPS injection is above 50 micrograms (per one gram creatinine , so 50 µg/g creatinine, see ch. 3.1.2.2), we know that the body needs help in excreting the poison, in order to avoid too much toxin assimilation in the brain. This is even more important when the other toxic components of amalgam like tin, copper, silver or also other substances like aluminium, formaldehyde etc also show raised concentrations .

By giving the antidote DMPS, the heavy metals are excreted in the following succession :

zinc - tin - copper - arsenic - mercury - lead - iron - cadmium - nickel - chromium

Copper Depot

A relative copper depot (measurable by DMPS-injection-test: copper level more than 500 µg/g creatinine) develops in every case of chronic metal poisoning, if there is a parallel zinc deficiency in the cell. The only other way of identifying zinc deficiency in the cell is by measuring the zinc level in red blood cells.

The copper depot disappears only when all toxic metals (arsenic, lead, cadmium, mercury, bismuth, tin etc) have been removed from the body, allowing the zinc level of the cell to return to normal. The copper depot is an indicator for metal poisoning.

DMPS does not lower the copper level directly. With a copper depot in the cell, the copper in the blood serum and the 24-hour-urine can be normal. This has nothing to do with a copper storage disorder (Wilson's disease).

4.2.2.2 DMSA-Test

Dimercapto Succinic Acid has an effect similar to that of DMPS. In Germany it is not yet available as a medication and must be ordered from a chemical supplier in powder form. DMSA binds the toxins that

travel via the liver and gall bladder into the intestines, enabling them to leave the body through the stool instead of going back into the blood and from there into the depot organs.

Toxin depots in the teeth or jawbones cannot be removed with DMSA, they need to be surgically removed before. Infants and children who are poisoned by maternal amalgam are detoxified best with DMSA.

Oral DMSA is counterindicated in MS cases
(instead : DMSA- or DMPS-sniffing)

Use :

Swallow 100 mg DMSA powder (a pinch) with some water. The excreted amount of poison is determined in the third stool after ingestion, this is the so-called mobilization stool (stool II). We compare this result with the reading from the so-called spontaneous stool (stool I) from before the mobilisation. The difference between the two shows us the increase in toxin excretion.

The difference between stool I and II also helps in determining when the next dosis of DMSA should be given. The poison excretion via the stool is usually higher than via the urine, especially in cases of metabolic disorders (ie colitis, schizophrenia).

Guidelines :

Difference between toxin level in stool I and II	DMSA dosis
up to 5 ug/kg	every 6 weeks
more than 10 ug/kg	every 4 weeks
more than 50 ug/kg	every 2 weeks

Stool test procedure :

Container I : collect stool sample (about one teaspoon) before
the treatment starts

Container II: send a sample from the third stool after swallowing
100 mg DMSA to the laboratory

Toxin excretion under this therapy should be controlled every
three months.

4.2.2.3 Laboratory Analysis

All removed tissues - the extracted dental root, the periodontium as well as the surrounding jawbone, the placenta or a tumor - all can be analyzed in the laboratory for accumulated toxins. If the samples are not preserved with formaldehyde, the accumulated formaldehyde can also be determined (in most cases it gets into the jawbone because of its use in endodontic treatment).

If the lab finds toxin accumulation, surgical removal of the focus is necessary.

Dental root

Chronic poison ingestion over the past years or dozens of years is best determined in the dental root. It is easiest to measure the metals. The severed tip of the root is pulverized in the toxicological lab and analyzed for 54 metals by spectrometry, of which 12 important ones appear on the printout.

In most cases the dental toxin levels are excessively high. Lead, cadmium, formaldehyde and aluminium are very important in order to be able to identify and avoid environmental poisons. Since zinc is needed for excretion of these heavy metals, the zinc concentration in the tooth is an indication for the amount of "antidote", that was needed for all the heavy metals so far.

Extremely poison-saturated roots always remain foci. The only viable treatment is their removal and routing the wound.

Do not discard the teeth. In legal disputes they must be examined for toxins. The degree of poisoning in the surrounding jawbone can be deduced from the dental root. Analysis of jawbone tissue is recommended. It indicates the degree of intoxication of the whole organism.

Bacteria and fungi

Since harmful bacteria (virus) and fungi grow around intensively poisoned roots in the jawbone, the dentist can take a smear sample (cotton wool in culture medium). The material is sent to the examining lab in a sterile tube. then the dentist should keep the wound open with a strip of gauze and antibiotic ointment, so that bacteria and toxins can grow out of the wound.

4.3 Proof of Toxic Effects

4.3.1 Allergy tests : Patch Test

An amalgam allergy of Type I is very rare, the most common are Type III or IV .

Allergy tests are not possible while taking anti-allergic medication ie cortisone, psychotherapeutic drugs, antiepileptica or immune -suppressive drugs.

The following substances should be tested for tolerance when doing an allergy test :

4.3.1.1 Amalgam Tests

- amalgam
- amalgam metals
- Hg-mercapto-mix
- organic mercury (Hg S)
- thiomersal (HgS)
- organic mercury (phenyl mercury acetate)
- Hg(II) amidochloride
- silver
- tin
- amalgam, gamma-2-free

4.3.1.2 Tests for Metals and Adhesives

- formaldehyde
- eugenol
- platinum
- nickel
- gold
- chrome
- palladium
- titanium
- benzoylperoxide
- methyl methacrylate

4.3.1.3 Tests for Home Toxins

- lindane
- pyrethroids
- nicotine
- PCP
- dichlofluanide
- phenol
- d-limonen
- coal tar
- alpha-pinen
- mercury

4.3.1.4 Therapeutica

DMPS

DMSA

gingko

selenium

spasmocyclon

vitamins B2 and B6

" B12

" F (essential fatty acids)

" C

zinc (zinc chloride)

4.3.2 LTT-Test

The lymphocyte-transformation-test is sensitive and specific for determining the cell division rate after adding the antigen against sensitized T-cells. Cell division is measured by the rate of radioactive installation of H-thymidine during DNA synthesis. If the cell-rate is higher than before the test, it proves that the lymphocytes were transformed by reacting with the antigen. LTT is a test for the cell memory.

MELISA (memory lymphocytes immunostimulation essay) is a modified LTT which proves a metal allergy. It has the advantage of supplying morphological proof for blastogenesis.

If in cases of severe allergy the patch test is too problematic, this test is an alternative.

4.3.3 Blood Tests

4.3.3.1 Alpha-1-microglobuline

Until now A-1-M was considered a tumor marker in medicine, because higher-than-normal readings (over 42) often coincided with kidney cancer (in dentists, for example).

We have found , though, that the antidote DMPS, given when A-1-M levels were above normal, causes significant excretion of kidney toxins via the urine, and that with each DMPS injection the Δ raised A-1-M count improved a bit. Analysis can be done with the urine, or, more exact, in the (heparin-) blood.

If the readings are above normal, amalgam fillings must be replaced at once with non-metallic material and the antidote must then be taken until the readings return to normal.

In such a case antidotes should not be injected but rather taken orally or sniffed, in order to cause intestinal instead of urinary excretion.

Abnormally high A-1-M level is a proof for poisoning. The higher the readings, the more serious the amalgam induced kidney damage is. After amalgam removal and detoxification, control analysis is necessary to see if the readings are now in the norm.

4.3.3.2 Glutathione - Sulfur - Transferase

GST is one of more than 50 detoxification enzymes. Mercury has a strong tendency to block this enzyme through a sulfur bonding. But this is also a protective mechanism for preventing the poisoning of the brain: GST boosts methylation and thereby brain intoxication.

On the other hand the reduced GST level is the cause for the non-excretion of other poisons , which then increase the toxicity of amalgam. Among these are formaldehyde, lead, cadmium, pentachlorophenol and many others.

We have found that the supplemental intake of selenium, the central atom of GST, or of GST because of an allergy is often very harmful, whereas mercury detoxification causes the GST level to rise.

Guidelines :	100 - 90 %	normal
	under 90 %	light poisoning
	under 70 %	heavy "
	under 60 %	severest "

A reduced GST level is proof for an amalgam poisoning.

4.4 Proof for Cure

An indirect proof for a toxic effect is always constituted by a changed diagnosis or the absence of symptoms because of exposure stop and the removal of depot toxins.

An alcoholic , for example, only sees the effects of alcohol when his liver counts return to normal and, for example, a sleeplessness subsides because of exposure stop. Or a smoker will see the damage caused him, when a chronic bronchitis and anorexia disappear after exposure stop.

It is the same for the amalgam patient: the most important proof for the causal connection is the changed diagnosis after the removal of the poison. Chronic amalgam poisoning, though, causes irreversible damage - depending on previous damage, genetical disposition, allergies and depot location. In addition, severely sick patients, for example with auto-immune diseases, only experience decided improvement after radical surgery (total removal), where all jawbone depots are cleaned out following the extraction of the teeth.

The healing process after toxin removal is the most important proof of poisoning.

He that heals is right.

Miracle Healers

Psychologists and psychiatrists look with jealousy upon the few dentists who remove amalgam with much experience and under triple protection, and install alternatives selected through extended allergy testing, and only for this are regarded as miracle healers for headaches, sleep disorders, depression, joint pain, rheumatic arthritis, paralysis, MS, diabetes, cancer and many, many other diseases. One day the whole building that is psychiatry will have to be built anew, when it will be accepted that these diseases are not hereditary, but rather that the dentist determined which disease developed. If he put amalgam into the teeth of the upper jaw, then psychological disorders develop; if he put it in the teeth of the lower jaw, immunological diseases ranging from rheumatic arthritis to cancer develop. It is never the mother who determines the childrens' diseases genetically, but rather the dentist, by implanting amalgam in various places (see dental chart Chapter 3.6).

5 THERAPY

Therapy Scheme

If positive,remove amalgam . . .remove toxin focus

chewing gum test	+	
DMPS/DMSA test	+	
patch test amalgam	+	
focus on OPT		+
focus on MRI		+
dental root analysis		+
autoimmune tests		+++
alpha-1-microglobuline		+
glutathione transferase above 70 %	+	
glutathione transferase above 60 %		+
palladium in evidence		+
pesticides "		+
solvents "		+
formaldehyde "		+

5.1 Exposure Stop

Amalgam, like asbestos, must be removed as early as possible.

The most important and decisive measure to be taken with any chronic poisoning or allergy is to stop exposure to the toxin.

It makes no difference whether the chronic poisoning was caused by alcoholism, smoking or amalgam. But in the case of amalgam, the toxin is still stored in the whole organism. The more exact the testing for the depot locations is done, the more successful the effort to completely avoid the poison will be.

The more competent the doctor is with the above diagnostic procedures, the better the patient's chances are of avoiding the causal poisons completely. Nothing else matters.

Who heals, is right

From the physicians who have great success in curing their patients we can learn what needs to be done in order to heal the sick.

Amalgam cannot be removed from the organism, only reduced.

In cases of allergies or autoimmune disease radical surgery is necessary in order to remove larger amounts of poison from the hardly perfused jawbone, whom antidotes cannot detoxify at all. This way, at least partial success can be achieved.

5.1.1 Amalgam Removal

In cases with superficial symptoms, amalgam removal means a correct removal under triple protection. In cases with organ damage the treatment includes correct removal of toxin foci.

Since during any kind of amalgam removal mercury and the other amalgam toxins enter the organism, remember this mnemonic :

The sicker the patient is, the less release of poison during amalgam removal can be tolerated .

Toxin release during amalgam removal

by drilling : 10,000 µg/kg stool mercury release per tooth
by extraction : 700 µg/kg stool "

Drilling causes large amounts of mercury from the depots next to the dental root to be set free, but also extraction releases some mercury.

Amalgam removal always under triple protection.

From the toxicological point of view, amalgam fillings are always a poison source, and therefore always have to be removed under protective measures (normally one quadrant a week) and replaced by a less damaging material that has been tested for its compatibility.

Protective material :

- kofferdam , heavy duty (silicon sheet)
- eye protection (swimming goggles)
- oxygen supply of 8 liters per minute (nose tubes both sides)

- hardmetal drill (sterile), high speed (not turbine)

Do not drill, only divide and then peel out into healthy tissue under strong suction .

Remove amalgam gently, not quickly.

Preparation

1. Have an OPT of all teeth made. Identify metals.
2. In case of muscular weakness or symptoms of paralysis , always have a magnetic image (MRI) of the head made. If there are small spots in the cerebrum, do not have any amalgam removed by drilling, instead, the tooth must be extracted after the amalgam tip is cut off.
3. Long-term testing for allergies against all dental filling materials.
4. Chewing-gum test for mercury and tin, possibly also lab analysis (lead, palladium) to evaluate the present state of intoxication (severe poisoning is in evidence when mercury and tin concentration together is higher than 50 µg/liter) and to prove the poisoning.
5. DMPS test per injection to detoxify very old depots in cases of: severe nerve damage (paralysis, blindness, deafness), immune system damage (baldness, cancer, AIDS). Should include analysis of mercury, copper and tin levels.
6. Have all poisoning symptoms documented by medical doctors (neurologist, dermatologist : glutathione-s-transferase in %, alpha-1-microglobuline, patch test for 7 days, etc.).

Amalgam removal only under triple protection !

Amalgam Removal

It is imperative to use the following :

1. Kofferdam (silicon cloth). Micro-engine and high speed, strong suction. Do not drill, but cut apart and peel off deeply into healthy tissue (no metal residues should be seen on the control OPT).
2. Oxygen bottle or air supply by pressure tube, 8 liters/minute, plus goggles to protect against mercury/tin vapors.

3. Take DMPS (DMSA), one capsule two hours before each session. At the end of the session, rinse the mouth with a sip of sodium thiosulfate (NaThioS), 10 %, 10-20 ml, swallowing a little bit at the end. Without previous DMPS injection, the removal can only progress slowly, quadrant by quadrant.

After Removal (= saliva free of metals)

- Extract all dead teeth and analyze them toxicologically for formaldehyde, arsenic, mercury, bacteria and perhaps palladium.
- Extract wisdom teeth including dental follicle.
- Amalgam filled teeth with infected roots (enlarged, piston-shaped, with bone transformations like pearls-on-a-string) must be extracted (first upper, then lower jaw). Metal-infiltrated bone sections must be routed out and the wound kept ^(very important) open _Δ for 2 to 4 weeks with gauze strips and antibiotic ointment; analyze gauze. Toxicological analysis as above.
- If there are tumors (cancer or other), have them examined for the amalgam components mercury, tin and silver.

Always examine extracted teeth for toxins and pus.

- After amalgam removal, have the teeth filled with metal-free synthetic material or, in case of a formaldehyde incompatibility, with cement as a long-term provisional filling for 2 to 3 years until the poisoning symptoms have clearly improved or until metals are not detected anymore in the jawbone.



- In case of immune- and nerve system damage, detoxify with DMPS:
in order to avoid an allergy, take seldom, but high doses. Every six weeks inject one ampule DMPS into the muscle. In case of kidney weakness take one capsule DMPS per week on an empty stomach.
- If there are foci in the brain, sniff four times a week from an open DMPS ampule, each time take six sniffs.
- In case of a zinc deficiency, take a zinc supplement (zinc aspartate
0 - 50 - 100
mg / day).
- Never selenium !

Only use alternative materials that have proven compatible
in allergy testing.

Triple protection and metal-free replacements are extremely important if the allergy test was positive or if there is a kidney disorder with raised alpha-1-microglobuline level.

5.1.1.1 Pregnancy and Lactation Period

No amalgam removal during pregnancy

Under no circumstances should amalgam be worked on during pregnancy, because the inhaled mercury vapors cause serious damage to the fetus. We often saw children with birth defects after unprotected amalgam removal from the mother. In case of tooth pain, the amalgam-filled tooth must be extracted to protect the child during pregnancy.

In order to prevent unnecessary poisoning, during pregnancy and lactation the open surfaces of amalgam fillings should not be brushed and mercury not released through fluoride toothpastes, grinding (occlusion device), chewing gum, through hot or sour foods(vinegar). DMPS/DMSA, vitamins(C,B) and selenium, which form the dangerous, embryotoxic organic mercury, are all absolutely prohibited !

Prohibited during pregnancy are :

- polishing amalgam
- toothgrinding
- gum chewing
- hot food
- sour food
- fluoride toothpastes
- DMPS / DMSA
- vitamins
- selenium

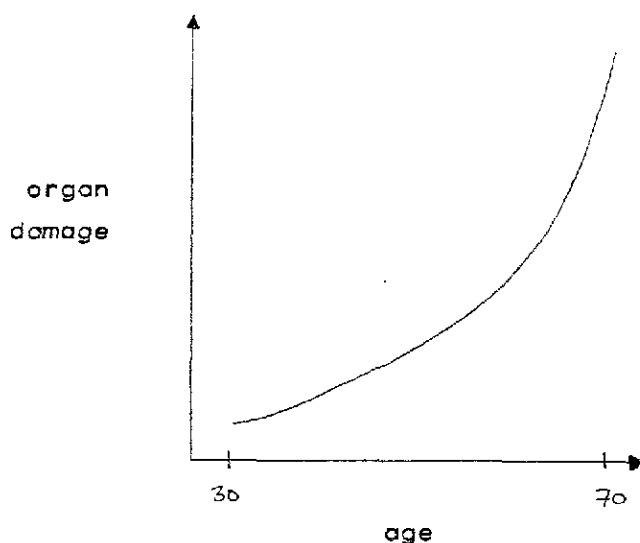
A diet rich in zinc and not chewing much are the only emergency measures feasible here.

Dental

5.1.2 Restoration of Toxin Focus Locations

Teeth are free of dental foci only until about age 30, then organ damage appears. When amalgam is involved, dental foci can develop in small children already.

An experienced person can identify foci in an OPT, the unexperienced see them in a bone scintigraphy (a radioisotope scan = considerable radiation exposure !).



When restoring locations of dental foci, it is also of great importance to know, which poisons (metals, solvents, formaldehyde, pesticides, wood preservatives, etc) are in teeth, gums and jawbone.

Besides amalgam, there are other metal alloys (ie gold or palladium, or nickel-chrome-molybdene) from inlays, crowns, bridges or prosthesis which can also cause diseases or block their cure. It is the doctor's task (together with the dentist), to recognize this and, if necessary, to recommend their removal and the correct replacement. Root-canal-treated/dead teeth and other toxin foci in the jawbone area (ie granuloma-like metal depots) should, toxicologically speaking, always be removed.

In patients with strong or even severe secondary amalgam disease (ie neurodermatitis, eczema, asthma, rheumatism, psychosis/depression, emotional lability, epilepsy, tumors, MS, ALS, Alzheimer's, Parkinson's), all metals in the dental area must always first be removed before tooth extractions or focus restorations and allergy, otherwise the metals will enter and stay in the wound cavity.

In cases with metal allergies, all metals must be removed before the extraction^{and} under triple protection.

Exception : acute emergencies, for example root infection.

Metal removal only under triple protection :

- 1 DMPS capsule before session
- 2 Oxygen, Kofferdam / "Clean-Up" (Scania dental)
- 3 Sodium thiosulfate

Experience shows, that the extraction of an affected tooth always offers the chance to get out a considerable amount of the heavy metals and other poisons that have accumulated in the jawbone. For this , it is necessary to keep the wound open for some time with a prepared strip of gauze, which will collect and bind poisons as well as bacteria, and which can then ^{be} analyzed in the lab in order to document the contained foreign substances.

Every metal (ie stomach drugs, auto emissions, passive smoking) that is assimilated by the teeth or the organism, also accumulates in all of the jawbone area. Even teeth that had never been treated are affected by this, even ingrown wisdom teeth. For this reason, every extracted tooth, the open wound, the removed jawbone tissue and the inserted gauze all should be analyzed for bacteria and fungi, and, by spectrometry, controlled for all toxicologically relevant materials.

The patient must be given the following things by the therapist for the appointment for extraction or focus surgery :

- 1 for/a bacterial and fungal culture: swab / sterile gauze + container for transport.
- 2 for the tooth : dry transport container
- 3 for the removed bone tissue : container
- 4 as wound tamponade : antibiotic eyedrops (ie gentamycin-cortisone-polymyxine eye drops)
- 5 sterile gauze; simple gauze strip one cm wide, without iodine, with container (this gauze and ointment will be needed also for changing the dressing every three days).
- 6 pre-adressed envelopes for mailing the samples to the lab
- 7 oxygen bottle with nose tubes for both nostrils, to take to the dentist, for oxygen supply of 8 l/min. This is especially important when palladium is to be removed - it is equally dangerous as amalgam removal.
- 8 DMPS capsule, to swallow before the removal, and NaThioS 10 %, 10 ml for rinsing the mouth after every metal removal.

Directly after extraction :

- First smear from deep within the wound, without touching the sides of the wound : bacterial and fungal culture.
- After this, the jawbone must always be cleansed and routed extensively and thoroughly by the dentist.
- If the tooth is discolored or brittle or if the root appears glassy, this indicates an inflammation focus caused by metals or pus. The jawbone vicinity and wound cavity must in this case be routed thoroughly.
- If technically possible, save fragments of the routed jawbone tissue from suction (discuss with dentist beforehand) and have them analyzed for mercury and other heavy metals (lab spectrometry), and also for formaldehyde if there was root canal treatment.

INFO: until about 1989, arsenic was used for endodontic treatments (today still, occasionally). In the 1980's dentists began to use formaldehyde instead. Root canal fillings can also contain amalgam or cortisone.

- After tooth extraction/focus removal, have a gauze strip put into the fresh wound, with antibiotic eyedrops thinly spread on it. Change the strip every three days. If despite this, the wound keeps closing, the granulation tissue must be removed by the dentist. As above, keep renewing the gauze every 3 days.

EXCEPTION: if there are maxillary teeth/roots that extend into the maxillary sinus, the hole into the neighboring sinus must be covered plastically. Here, the wound is closed with stitches and only one strip is put in and not renewed.

Never put in two strips per wound and always make note of the length of the strip, to avoid a strip being forgotten inside, and the superficially closed wound suppurating and hurting for months.

If certain symptoms recur, that correspond to this particular tooth, (ie, 8 = psyche, heart, central nervous system) or the symptoms become even worse, a small opening has to be made in the wound after 2 to 4 months, for example with a small drill, in order to stimulate blood circulation. Then proceed as described above, as after a fresh removal.

If there is no organ irritation, have an OPT made after completing the dental restoration treatment. If a focus is visible, the inflammation needs to be opened surgically.

Laboratory Instructions:

First wound gauze (three days after extraction) : send in for examination only that part of the gauze which had been at the bottom of the wound, cutting off the rest. Analyze for mercury and heavy metals (spectrometry) and bacteria.

Analyze approximately the 5th gauze (around the 15th day after extraction) once again in the lab for those metals whose readings were high in the first sample. If only a few metals show high levels, have only these analyzed in the next analysis(analysis for palladium is as expensive as a multi element analysis, and also included in it).

As soon as the results of the last two examinations are inconspicuous, (within the "norm"), the ointment can be omitted. The gauze, though, must still be renewed until it will not fit anymore into the closing wound and falls out by itself.

But if the wound continues to secrete foul-smelling substances(analyze once more for bacteria/fungi) or if the wound edges are discolored red/blueish (mercury), and the results from the last gauze still show higher than normal levels of metal excretion, then the gauze and eyedrops must be put in for another 2 to 3 weeks , and so on, until a gauze is within the "norm", ^{that is,} mercury less than 10 µg/kg or bacteria-free.

Bacterial/fungal culture

If pathogenic bacteria and/or fungi were found on the first smear (swab or gauze), the usual antibiotic ointment may need to be replaced by one that has tested effective against these particular pathogens.

Granulation tissue

The dentist must examine the jawbone weekly for granulation tissue. If it has formed, he must remove it.

Each surgery on nests of toxins causes a recurring of the previous organ complaints, such as rheumatism, infections, heart disorders, fatigue, weakness, organ pain (breast, stomach), MCS, and many others.

A focus operation always causes focal irritation.

If after tooth/focus removal the symptoms improve or disappear and then reappear after some time (3,6,or 12 months or more), and are resistant to therapy(DMPS etc), then the old wound must be reopened and/or a small opening made (post-treatment as above).

Autoimmune Diseases

Successful therapy in autoimmune cases consists of total removal of all proven causal allergens from the jawbone.

In some cases a mutilating operation, removing all intoxicated dental roots, is unavoidable. Until the jawbone has healed completely, a generalized allergy often may not even permit the installation of a full denture. Here the routing of all allergy nests is especially important. Sometimes, choosing a less allergy-prone denture material helps .

5.1.2.1 Surgical Methods

<u>Procedure</u>	<u>Old School</u>	<u>New School</u>
preparation	single x-ray	OPT
focus localization	(electro-) acupuncture	OPT + experience through analysis or scintigraphy
anesthesia	cheapest brand	least allergenic brand
operation	"saliva disinfects everything"	absolutely sterile procedure: gloves, face mask, sterile cloths, surgical instruments individually wrapped, new instruments for each tooth, oxygen
multiple rooted tooth	extract all at once : painful	divide roots before extraction: time consuming, painless
root contains toxins	"no such thing"	rout down to the solid bone; keep wound open and renew gauze and ointment for six weeks
laboratory analysis	"unnecessary" tooth is discarded	first strip after removal to the lab dry tooth to the lab
root suppurates	"heals itself", close with stitches, perhaps a penicillin ^e pill before (98% of bone bacteria do not react to penicilline anymore)	wound smear to the lab remove infected bone tissue thoroughly and keep open with gauze and antibiotic ointment, then proceed according to lab results

Problem/ Procedure	Old school	New school
Aftercare	none	every 3rd day new gauze strip with tested antibiotic ointment (germs can change)
Pain	pills	on the first evening one suppository Diclofenac
swollen cheek	yes, cool with compresses	no, does not apply
nutrition	diet, no milk products, etc	eat everything as usual, rinse with water afterward
organ/joint pain later	"no connection"	wound revision according to where pain is until painfree

5.1.2.2 Therapeutic Procedure for Foci and Teeth

Step	Treatment	Result if focus remains untreated
1	remove amalgam and palladium foci around dental roots remove metals under protection	Maxilla: severest nerve damage Mandible: severest immune damage
2	if palladium depot in maxilla, remove palladium foci around dental roots	severest immune damage
3	if amalgam depot in maxilla, remove amalgam foci from root vicinity	Maxilla: nerve damage Mandible: immune damage
4	remove wisdom teeth (lateral) that carry a focus	Chronic Fatigue Syndrome, MS, low enrgy level
<u>or</u>	remove teeth 3 lateral in maxilla with foci	MS , vision disorders
5	remove teeth 6 with maxillary toxin-filled cysts	severest allergies
<u>or</u>	remove teeth 1 with foci next to olfactory nerve, maxillary and mandibular	hypersensitive sense of smell
<u>or</u>	remove toxin foci in mandible (they block nerve paths)	severest immune damage
6	remove 6's with toxins in root vicinity	allergies

Step	Treatment	Result if untreated
7	remove 7's with toxin-filled cysts	Maxilla: heart and ear disorders
<u>or</u>	remove 3's with toxin-filled cysts	Maxilla: vision disorders
8	remove root-canal-treated, dead, formaldehyde-filled teeth	allergies, cancer risk
<u>or</u>	remove root-canal-treated, dead, arsenic-filled teeth	high cancer risk
<u>or</u>	extract dissolved, intoxicated dental roots	depends on location
9	extract teeth whose fillings are very close to the root and that reveal a root depot	depends on location
10	remove foci that have broken into the paranasal sinus	immune disorder according to location
<u>or</u>	remove implantates with typical allergy depots in bones (allergy tests positive)	allergic brain symptoms
<u>or</u>	treat inflamed nerve exit point	rheumatic pain
	*** *** *** ***	

5.1.2.3 Convalescence Time

Without additional measures, the convalescence time is at least 5 years. Usually, the remaining foci cause new trouble during this period.

Certain cure is possible only by complete removal, with full dentures, here convalescence time is one year.

It is about three years, when a partial restoration through removal of all metals is done; afterwards check whether the toxins have collected around a remaining tooth or if pus has formed.

One ampule DMPS shortens convalescence time by about 3 months, three capsules DMSA by about one month.

After total detoxification of depots, the diagnostical tests improve :

Test	Improvement	Convalescence Time, minimum
OPT (no pus, =black appearance)	no metals (white appearance)	1 year
MRI head	no metals (white imaging) reduction of spots	3 years

Test	Improvement	Convalescence time
SPECT	functional failures	child: $\frac{1}{2}$ year adult: 2 years
DMPS test	after jawbone restoration	up to 1 year
MELISA- allergy tests	after cause removal	2 years

Improvement of symptoms occurs long before the normalization of symptoms sets in, which means that only long after the patient feels well again, are the test results normal.

5.2 Depot Detoxification

5.2.1 DMPS

In case of a positive DMPS-test, a DMPS therapy can follow, but only after exposure stop, that is, complete removal of amalgam. The antidote is given in increasing time intervals. Depending on toxin excretion, in the beginning according to the following scheme :

- twice weekly (Hg in urine II above 500 $\mu\text{g/liter}$)
- every 4 weeks " 200 "
- every 6 weeks " 100 "
- every 3 months " 50 "

In case of metabolic anomaly the following stool levels apply :

100 - 50 - 10 - 5 $\mu\text{g/kg}$ stool

CAUTION

If pimples appear on the skin, or mucous membranes break open or headaches develop - these are the signs of a DMPS allergy - DMPS must not be given anymore. Since these symptoms are the result of a sulfur allergy, no other mercury antidote can be given either, since all of them contain sulfur. Here the surgical removal of amalgam from the jawbone should be done very thoroughly (see 5.1.2 Focus restoration).

A DMPS allergy is predictable for patients that are allergic to thio-mersal.

DMPS therapy is prohibited and worthless as long as the patient has palladium in his mouth. The same goes for gold - it binds amalgam.

5.2.1.1 DMPS Sniffing

The contents of one ampule DMPS, transferred into a glass with a screw-lid, serve for sniffing via the nose, not inhaling deeply into the lung though. In this way, passing along the olfactory nerves, minuscule amounts of antidote reach the most affected parts of the brain, especially the brain stem.

The best effect is achieved by sniffing six times. Then the third stool is analyzed for mercury in the lab. According to success and lab result the procedure can be repeated about every 4 weeks.

DMPS is the most effective against memory disorders, brain function disorders and depression. It has often achieved a substantial temporary improvement in cases of severest poisoning, where the patient can not muster the strength for amalgam removal (ALS).

Sniffing is also helpful when palladium was also in the mouth, whereas DMPS injection is contraindicated in this case.

5.2.1.2 Jawbone Detoxification

Formerly, DMPS was injected painfully into the jawbone. Today we know that the same effect can be achieved by drilling a round hole into the jawbone and stuffing a strip of gauze, with tetracycline eyedrops on it, into the hole, and renewing the gauze and eyedrops every three days. In this way, a much larger amount of toxin is removed, at its source, than with injected antidotes.

5.2.1.3 DMPS Dosage

The frequency of DMPS injections depends mainly on its success. The surest criterium for this is the patient's condition.

The most-improved symptom, for example an improved eyesight, or better mental functioning, worsens again after the DMPS effect wears off after some weeks. With repeated injections, the intervals become longer, ie 4,4,6,6,8,8,12,12,16,16 weeks. If the mercury excretion was determined after DMPS, the excretion level will correspond with the severity of the recurring symptoms. Only if, after DMPS, toxins are still excreted (more than 50 ug/kg creatinine mercury), can DMPS be given again.

DMPS and DMSA as a long-term therapy for chronic poisoning must be given in large intervals only !

5.2.1.4 DMPS Allergy

DMPS is a sulfuric salt and binder for metallic salts that, with repeated intake, can cause allergy. The first harmless sign of an allergy consists of pimples on the skin, which later on can also appear on mucous membranes. Lips, anus, vagina or penis swell painfully, the whole digestive tract hurts.

In extreme cases a toxin-related brain edema with headaches can develop. Here the brain tomography temporarily shows a few single spots. All this disappears without any treatment, but the patient must never be given an antidote again! The only help here consists of routing the jawbone.

For serious, poison-related diseases, where DMPS is urgently needed to boost excretion, it must be used only rarely and in the highest possible dosage, in order to avoid an allergy with the above symptoms.

Frequent small doses in the form of capsules lead to allergy particularly quickly. To lessen the risk of allergy, the patient should not take any other medication during ^{the} DMPS treatment period.

In case of an already existing allergy against thiomersal(Hg-S), allergic reactions may ensue after DMPS injection also. Increased side effects, at least, can be expected.

In case of a DMPS/DMSA allergy, the antidote can be sniffed (six times, every four weeks).

5.2.1.5 Trace Elements after DMPS

DMPS does not cause trace element deficiency

DMPS does increase excretion of zinc and copper, in millionth-gram-amounts; but they are found in the organism in 1000 times greater quantities. Supplemental intake of zinc is ^{never} necessary in connection with the rare DMPS dose against chronic poisoning. Only when treating an acute poisoning with 3 to 20 doses of DMPS per day, can zinc supplements be indicated. Selenium and magnesium are not excreted by DMPS. Amalgam often leads to a zinc deficiency, which is relieved by DMPS.

Dosage :

50 mg zinc-aspartate per 10 kg bodyweight, for 6 weeks if deficiency is severe , for example 0 -2 - 4 pills of 50 mg, later half (0-1-2). After 5 pm, zinc is assimilated better by the blood, also do not eat for two hours before.

Copper excretion after DMPS

The level of copper excretion directly after DMPS injection is an indication for the extent of zinc deficiency in the cell. Here the total copper excretion in the 24-hour-urine can be normal. Persistently high copper levels after DMPS indicate still-remaining toxin depots which constantly eat up zinc. Only replenishing the zinc or continuing to inject DMPS without removing the poison sources would mean veiling disease-causing factors (jawbone depots, car emissions, wood preservatives, aluminium, formaldehyde, etc). High copper levels constitute the longest-enduring laboratory indication of an amalgam poisoning.

Instead of repairing secondary damage in arbitrary locations, the removal of the true primary cause is what helps.

The manufacturing industry does not love this environmentalistic principle, because they mistakenly assume that they would earn little this way. With all new materials, though, their profit margin is even higher. Avoiding secondary damage saves much money.

5.2.2 DMSA

DMSA, the salt of the succinic acid of dimercaptan, being a pure chemical compound, is ideal for patients with small financial resources. Like DMPS capsules, it boosts the liver-gall-excretion of mercury, lead, tin, cadmium, etc and, like the capsule, is assimilated by the blood with some divergence. In China DMSA is available for injection, but not in Germany. DMSA increases the excretion of the highly toxic mercury from the brain severalfold. This is very positive for patients with neuropathic problems. MS patients, though, very often suffer an episode, caused by the rapid brain detoxification. For this reason DMSA is absolutely prohibited when foci are identifiable on the brain tomography. It is ideal for the treatment of children (also sniffed), with analysis of the following third stool. DMSA does not detoxify the whole body as well as ^ΔDMPS injection.

DMSA is given orally once every 1 to 4 weeks to swallow (100-200 mg). Drink a lot afterwards. Examine third stool for mercury.

DMSA is a chelator and can, because of its low allergic tendency, be given for some time even when a DMPS allergy has developed (but contraindicated with intestinal diseases). In case of a DMSA allergy all antidotes are prohibited.

5.2.2.1 DMSA Sniffing

As an alternative to DMPS, 100 mg of DMSA powder can be dissolved in a spoonful of water and sniffed like DMPS.

Mercury excretion in the third stool is then measured in the lab.

5.2.2.2 DMSA Allergy

This allergy can range from a completely harmless skin problem (pimples) and mucous membrane sores (mouth, genitalia) to brain edema (water inclusions on tomography) with strong headaches and brain function disorders when taken steadily and repetitively. Only strict avoidance helps here. The substance can never be taken again.

Possibly one suppository diclofenac 50 mg once or twice every 3 days.

5.2.2.3 Infant detoxification

The real victims of our negligence with nerve poisons are the newborn children.

If poisoned, they

- are restless
- do not drink well
- do not develop well
- suffer from visual, hearing and skin disorders
- tend to infections

Any chronic illness in a child and every mother that was not detoxified of heavy metals before pregnancy, give cause for detoxification of the newborn child. The first child receives up to 40 % of the maternal depot toxins. The earlier detoxification starts, the smaller the late problems. Since unpleasant side effects never appeared during correct detoxification, one can always make a trial, if in doubt, to see if a symptom will not regress.

Detoxification is definitely mandatory, if the previous child, or the twin (!) died of crib death, or in cases of brain damage (hydrocephalus, for instance), organ damage, febrile convulsions, epilepsy, neurodermatitis and candida infection.

The treatment of children is, of course, only an emergency measure in cases where the mother refused treatment before her pregnancy. The child must suffer the errors of the mother.

As the body is cleared of the poisons, they can be detected in the stool or urine :

DMPS-test for newborn children



1. For Feer-syndrome :

Let the baby sniff 3 times from an open ampule while sleeping. Have the third stool after analyzed for mercury. Poisoning is in evidence if mercury is at all detectable (detection limit = 0.5 µg/kg stool). Here, especially the poison assimilated in the sniffing area (brain stem , cerebellum), which causes the Feer-syndrome, is excreted.

2. For organ damage :

DMPS into the muscle (empty bladder before) :

- age 2 1 ml = 50 mg
- age 4 2 ml = 100 mg
- age 6 3 ml = 150 mg
- age 84 ml = 200 mg
- beyond.... one ampule

Save the urine passed one hour after injection, analyze for mercury and copper. Here the kidney in particular is detoxified, and later, by redistribution, also the brain.

DMSA test for children

Brain detoxification is less pronounced here than with DMPS sniffing (Feer syndrome), but kidney and liver are detoxified at the same time.

Newborn children : 100 mg (15 mg/kg weight)

From age 6 : 200 mg (6 mg/kg weight), to be taken with the food, analyze third stool for mercury.

Consequence

Always when mercury is detectable, the antidote must be given repeatedly and in large (!) intervals of 4 to 12 weeks, in order to remove the nerve poison from the brain. If accumulated in organs, any amount of mercury will damage the child's brain.

Since the mother passes up to 40 % of the total mercury concentration in her body on to her child, we find, on the average, much higher levels with mobilisation tests in newborn children than in adults (up to 2500 µg Hg/ creatinine), even though children are much more sensitive to mercury than adults.

5.3 Therapy for Environmentally Damaged Patients

Poison victims that do not care for their bodies as if they had suffered a heart attack, cause themselves more damage than the poison did, by taking high doses of antidotes, vitamins or trace elements or with electrotherapies ! Poison victims need to be protected from senseless curative attempts even more than from poisons.

Every chronically poisoned patient must realize, that therapeutic attempts hurt them more than they help them.

Brain intoxication - Allergy

It has been shown, that many medications cause unwanted redistribution in the organism of the toxins - especially accumulation in the brain - like vitamins and trace elements do with amalgam patients. In addition to this, amalgam victims proved allergic in patch tests to practically all artificially supplemented dietary additives, which gives a medical explanation for the deterioration of symptoms after their intake. In many cases both side effects concurred.

This also explains why environmentally poisoned patients usually feel worse after such non-specific therapeutic attempts than when they do nothing.

Ecological hypochondria

Frustrated doctors try to explain therapeutic failures with terms like the above, and send for a psychiatrist because of their own incompetence.

The doctor's best customer

An additional difficulty with environmentally damaged patients lies in the fact that they tend to go to very many ^{doctors}, either simultaneously or in succession. It is not rare for someone to have been to 50 to 75 physicians. Each doctor prescribes a medication or method of his school. These different methods are then applied simultaneously or in short succession, before the effect can set in.

Good nutrition, though, would be the cure. We learn from those patients that become healthy, that after correct exposure stop and a short depot detoxification, only a healthy, balanced diet - whose effects one notices immediately after the meal - will bring decided improvement in health. But a healthy diet by itself

will not bring about improved health without removal of toxicological causes.

Prerequisite for changing one's eating habits after cause removal is a certain mental flexibility to move away from the artificial chemistry and towards a natural life. It is then quite easy to look up in food charts which nutritional elements are found in which natural foods, and what to avoid in order not to impair their effect.

Paracelsus' rule still holds true :

Your food shall be your medicine.

5.3.1 Zinc

Zinc and selenium are trace elements which ^{can bond with} amalgam, lead (car emissions), cadmium (plastics), PCP (wood toxins) and others and which are then unavailable for the organism. In cases of proven poisoning by mercury, copper, cadmium or lead, zinc level in urine should be at least 400 - 600 µg/g creatinine. A zinc-selenium deficiency is a clear indication of chronic poisoning. Much more serious, though, are other signs such as a blockade of the protein metabolism of the brain (acetyl-coenzyme-A).

Zinc level in urine after DMPS (urine II) should be between 10,000 and 20,000 µg/g creatinine !

Zinc assimilation is impaired by:	soy milk products (calcium) cheese grain flakes raw oats celery dark bread fibre-saturated diet bran
-----------------------------------	--

Zinc assimilation is aided by:	vitamin D
--------------------------------	-----------

Zinc eaters :	lead cadmium formaldehyde phosphate fertilizers mercury tobacco smoke
---------------	--

will Zinc aid :	growth physical strength building of proteins, fats and carbohydrates sperm production male & female genital function
--------------------	--

Zinc aids (continued) :	touch, smell, taste, sight senses appetite excretion of lead, cadmium & mercury
Rich in zinc :	meat and fish with little fat
Poor in zinc :	vegetables
Zinc excretion is ^{increased} by :	stress fasting birth control pill alcohol & cigarettes sweating excessive physical exertion hormonal change
Zinc deficiency :	the younger , the graver
Zinc deficiency effects :	acne (mercury) proneness to infections feer-syndrome (m.) hair loss (m., formaldehyde) dry skin (" ") high blood pressure (lead, m.) hyperkinesia (" ") brittle nails (m., form.) osteoporosis (cadmium, m.) small penis and testicles in boys, impotence, hormonal disorders sterility (m., cadmium, PCP) schizophrenia (m.)

5.3.2 Selenium

was once

Selenium against amalgam poisoning given by American and Scandinavian dentists as an emergency measure, because DMPS, the medicine that is really indicated here, ^{was} not available there at the time.

Since selenium is a zinc-eater, the 200 times more important zinc must be replenished in such a case by supplementation (selenium in the morning, zinc in the evening).

Selenium amplifies the neurological symptomatology, weakens the physical symptomatology, meaning: it aids the accumulation of toxins in the brain , it poisons the brain.

Selenium is a "poisoner". After taking selenium, the poison that accumulates in the brain can only partly be flushed out with DMPS.

Organic selenium as found in food is beneficial, while anorganic selenium in pills (with sodium) enters the brain.

Selenium is prohibited in case of brain symptoms.

In accordance with today's blind belief in chemistry, many amalgam victims take selenium also here in Germany, while leaving the toxin depots in their jawbones. While zinc is needed by 200 enzymes for the organism's immune system, selenium relieves only one single enzyme deficiency related to amalgam, the glutathione-peroxidase. Selenium is cancerogenic and aids the accumulation of mercury in the brain as well as inhibiting its normal excretion. Zinc and selenium are antagonists. This means that taking selenium reduces the zinc level in the body. Selenium intake can cause headaches, depression, sexual disorders, etc., in other words : the symptoms of amalgam poisoning of the brain.

Selenium encourages Alzheimer's disease

5.4 Detoxification of Environmental Poisons

After certain exposure stop :

1. Detoxification of the readily accessible depots, like liver and kidney with :

- a) DMPS ↗ against mercury and also tin, lead, palladium, bismuth
- b) ↘ against aluminium Desferroxamine
- c) Zinc ↗ against cadmium
- d) Coal " PCP, PCB, lindane, dioxins, pesticides, solvents
- e) Disulfiram " nickel

2. Detox of fat depots

- a) Coal and fasting in case of PCP (measure before, with paraffine oil), lindane, PCB, dioxines, pesticides, solvents
- b) DMSA (DMPS) orally plus fasting against all metals

3. Detox of brain

- a) Clean surgically (root) poisoned dental roots and renew antibiotic gauze strips for 14 days (analyze extracted roots toxicologically)
- b) against metals , give antidotes in very large intervals (ie, every 3 months). Sniff DMPS in large intervals.
- c) against solvents, take coal and paraffine oil every 3 months for 3 days while fasting

5.4.1 Ginkgo Biloba

Ginkgo biloba, the only plant resistant to environmental poisons, has proven helpful against dangerous, poison-related brain malfunctions in our experience (memory disorders, vertigo and tremors - all in conjunction with headaches). In most cases, though, additional headaches appear if the ^{manufacturer's} recommended dosage is not adhered to. The improvement of the metabolic functions in the brain and of the blood consistency should unfold slowly. We recommend during the first 6 weeks :
3 times $\frac{1}{2}$ tablet Tebonin forte daily.

5.4.2 Calcium Antagonist

Since mercury increases the influx of calcium into the cell, neurological disorders can result as well as a tendency to brain- and heart infarction. Calcium antagonists can counter this effect of the poison. Over a long time, though, they will encourage osteoporosis.

Amalgam patients can tolerate only small amounts of calcium antagonists, for instance 3 times 200 mg spasmocyclon .

The positive effect is amplified if Ginkgo and calcium antagonist are given together. The effect will only manifest, though, if all the amalgam was completely removed and the body detoxified.

5.5 Metal Intolerance

- Identification:
- metal presence on OPT
 - metal foci on dental root ends on OPT
 - metal foci on MRI
 - abnormally high saliva test results (saliva II)
 - quantitative analysis of teeth, bone, tissue
 - metals positive in patch test (after 7 days)
- Treatment:
- remove all metals from mouth under triple protection
 - antidotes, if the mobilisation test shows high toxin levels (DMPS, desferroxamine)
- Prevention:
- no metal bridges or braces or other metals into the mouth
 - no implants with metallic surface (titanium)
 - avoid electric circuitry close to you at home
 - no metals on the body (earrings)

- Prevention: (cont'd)
- no electrotherapy (hydroelectric bath)
 - no electroacupuncture
 - reduce time* - *in front of monitors*
 - no microwave ovens or mobile telephones

5.6 Senseless Therapies

Senseless therapies are curative attempts that not only do not help, but usually cause considerable damage. Doctors will often prescribe useless therapies when they suspect the patient to be a hypochondriac.

1. Acupuncture: is damaging in case of a nickel allergy if the needles are made of nickel; particles remain in the skin
2. Herbal teas: severe allergies can cause tremors and vertigo, as we observed with horsetail tea
3. Homeopathy : the father of homeopathy, Hahnemann, recommended in cases of mercury poisoning , to eliminate the cause (exposure stop), followed by sulfuric liver (DMPS/DMSA). Under no circumstances renewed introduction of the poison. This is of great relevance for allergic patients since we proved all of the remedies that we analyzed to have wrong information on the label.

The intention of homeopathy, according to Hahnemann is the treatment of the clinical picture, and not the conventionally practiced symptom-fixing. The toxin accumulation in organs cannot be reduced by homeopathy.

It would be crazy to introduce additional mercury (or tin, silver, copper) into the organism after amalgam removal, when the body is freshly, acutely poisoned by the amalgam. This always causes a substantial worsening. A renewed, low-dosage introduction of the poison cannot achieve any kind of improvement, neither biochemically nor toxicologically nor concerning the symptoms. Countless patients that became even more ill, told us this.

Since a mercury allergy always also involves an allergy of the brain, the allergen should never be given additionally. STRICTLY PROHIBITED IN CASE OF ALLERGY !

3. Homeopathy (cont'd): Homeopathic remedies can contain huge amounts of mercury (D 500 : 122 μg).
4. Anthroposophic medicine: Works with high mercury amounts, thereby poisoning their helpers and the dentists.
5. Injections : Prohibited in case of nickel allergy, because the needles are made of nickel and traces remain in the skin. Ampule contents are often preserved with the allergen formaldehyde.
6. Electroacupuncture : This is one of the most common methods of deceit with metal poisoning victims. Each therapist comes up with different results. It is cheaper, and just as harmful, to put a mobile phone under your pillow.
7. (Psycho-)kinesiology : Another common fraud with metal victims. As in electroacupuncture, there are no verifiable results, everybody measures something else, no cures are achieved. The time-extended patch test is an alternative.

Medications, that cause the toxin to move about in the body :

1. Selenium, supplemented: all selenium preparations available on the market contain sodium selenide, which transforms anorganic mercury into organic (methyl-) mercury, which, instead of being continually excreted via kidney and intestine, like organic mercury, is accumulated by the brain and is highly toxic. Organic selenium, on the other hand, from grains, fish and meat, is very healthy.

Selenium supplement is prohibited with brain symptoms

Correspondingly, this applies to all artificially supplemented trace elements.

2. Glutathione supplement: Thomas Baillie (University of Washington, Seattle) discovered in 1992 that late manifestations are the result of the formation of a transportation compound of the toxin with the body's own antioxidant glutathione, because glutathione forms a loose bond with the toxin and the conjugate is transported with the blood to the remotest tissues. There the compound breaks up again and releases the toxin, which can now connect again with the sulfhydryl groups of each cell in more than 50 places. Excretion is delayed by glutathione supplementation.

Patients with severe chronic poisoning show a reduction of their glutathione level whose extent corresponds with the severity of their poisoning. As the body undergoes detoxification, the glutathione level rises accordingly. This is very important because of the increased cancer risk that a lowered glutathione level brings with it.

Glutathione supplements are usually detrimental because of an allergy against glutathione. The same goes for all artificially supplemented vitamins.

3. The allergy rate is highest with the B and C vitamins.

Artificial vitamins cause the toxins to travel to the brain.

4. Oil flush : has been proven not to aid detoxification, although it has a soothing effect when the oral mucous membrane is damaged (also for dentures).
5. Chlorella : 70 % of our patients have an allergy against it. Green salad contains chlorella, and is much cheaper. Detoxification is certainly not possible with chlorella.
6. Coriander : does not detoxify. 80 % of our patients were severely allergic to it. Bread with coriander is cheaper. We have not heard of any patient worldwide who improved with coriander.

5.7 Ten Rules for Amalgam Victims

1. In case of nerve or immune damage act at once.
2. Toxin removal only under triple protection and after OPT.
3. Strongly intoxicated dental roots should be extracted; do not drill.
Every diseased or dead tooth also affects other organs.
4. Permanent alternative materials only after preliminary allergy long-term testing.
5. Repeated lab tests before and after the treatment, to prevent being branded as mentally ill (chewing-gum test, DMPS test with stool analysis, metals in dental root, 7-day allergy test).
6. Fresh, healthy foods instead of vitamins and minerals from pills.
7. DMPS-therapy only after removal of all metals. Give DMPS very rarely. For brain symptoms, sniff DMPS.
8. Fight the cause instead of trying make-shift therapies like acupuncture, bioresonance, homeopathy, psychotherapeutic drugs, etc .
9. Removable dentures prevent renewed decline of health and promise the best possible healing.
10. Careful selection of dentists. Criteria : provable success in the treatment of severely poisoned amalgam patients (new school).

6 ALTERNATIVES

6.1 Contraindications for Dental Materials

<u>Material</u>	<u>Side effects</u>	<u>Prohibited with</u>
Gold	Autoimmune diseases	Allergy to metals
Indium	"	"
Ceramics	Beware of palladium underneath !!	Aluminiumallergy
Synthetics	Allergy	Methacrylate allergy
Latex dentures	"	Gutta-percha pins in devitalized teeth
Palladium	severest immune and nerve damage, auto- immune diseases	always prohibited! allergies to metals
Platinum	Autoimmune diseases	allergy to metals
Titanium	"	"

Never use metals as a dental material !

Test synthetic materials for compatibility before use.

7 THERAPY RESULTS

As in all cases of nerve or immune system damage where the causal toxin is removed, the amalgam-related damage as well can be reduced by timely prevention and therapy.

(Many amalgam related diseases are not yet recognized and clinically documented. Owing to the biochemical action mechanism of amalgam and the extremely varying reaction patterns of human beings to nerve poisons and genetic defects, these diseases must number in the thousands.

Mercury is transformed into organic mercury in the intestines and in the brain, and ^{then} depending on the patient's frailty, damages the genetic material of every single cell (spot mutations). The smallest imaginable quantity of poison is sufficient. This is the trigger for various metabolic disorders with enigmatic "syndrome" names. The only thing they all have in common is that their cause is unknown. As we know, a toxin-related organ disease is, as a rule, not investigated, this would not conform to our philosophy, we would have to change our way of thinking completely. Poison victims are still often seen as cranks.

7.1 Allergies, Feer, MCS

Mercury allergy is exceptionally common. But it does not affect the cornea, on which dermatologists mostly conduct their tests, rather, it affects the brain (neuro-allergy, multiple chemical syndrome). This is called Feer-syndrome.

Feer-Syndrome

Initially this was the amalgam poisoning of children through the mother or from medications containing mercury. The poisoning, though, is exactly the same in adults.

The Swiss pediatrician Feer discovered this syndrome in the 1920's in small children. These children had been given ointments containing mercury. They became restless and irritable, reacted hysterically, did not eat, slept badly, and many died. After coming off the ointment, all the children became well (Franconi England, 20,000 children, 1930's). Only the children of amalgam-carrying mothers became ill again, after this. The previous damage plus the additional poison caused this brain poisoning.

Today the Feer-syndrome in children is circumscribed with endless terminology, in adults no physician recognizes it, since it is described

only in the pediatric literature. Since toxin excretion is not extremely high, but the brain symptoms are extreme, the toxicological/allergological picture must be seen as a nerve poisoning. Amalgam removal and DMPS improve the clinical picture decidedly, but complete cure is not possible because of the frequent mercury contacts (tetanus vaccination with Td-pure). The most common effect is a formaldehyde metabolism disorder, caused by the mercury-related folic acid deficiency.

Symptoms:

lack of appetite
 motoric disorders
 hypertension
 fever
 fingertips moist-red and painful (morbus raynaud)
 coldness
 weight loss (anorexia nervosa)
 limb pains
 hair loss
 skin eczema
 skin flaky
 tachycardia (racing heart)
 cerebral infection
 hypersexuality (masturbation)
 itching
 cramps, epileptiform
 paralysis (ataxia, steppage gait, polyneuritis, polyradiculitis, Landry)
 photophobia
 chronic fatigue
 stomatitis
 muscular weakness and wasting
 furry feeling, limbs
 irritability
 autonomous nervous system, damage to
 pain, spear-like
 perspiration
 salivation
 character change (depressions, crying, negativism, sleep reversal, apathy)
 death by respiratory paralysis
 lacrimation
 tooth loss and loose teeth
 tremors, trembling
 blood sugar level disorder

Proof :

If a newborn child has assimilated amalgam in the pregnancy, UBO's (unknown bright objects) and foci are always observed in the brain stem and cerebellopontile angle on a brain MRI, the so-called Feer-syndrome. If additional nerve poisons enter the picture, ie if amalgam is laid or removed, without protection, then the UBO's become large foci, this is then called a multiple sclerosis or encephalitis disseminata.

The clinical history tells us much about the causes.

In adult cases of MCS, amalgam, besides the other inhaled toxins, is accumulated in the olfactory nerve and detectable by a laboratory. Shortening of the olfactory nerve and sniffing of DMPS can detoxify.

Skin tests

An allergy against pure mercury is rare, it is most often against the multitude of organic and anorganic salts with mercury, tin, silver and copper which develop on the amalgam's surface. For this reason the following test is recommended at the dermatologist :

Take fragments of your own removed amalgam, ground to dust, and have them put on the skin of your back, under a plaster tape with cocoa butter or vaseline for seven(!) days. Psoriasis-like reaction. This test was positive in all of our poisoned patients.

"Acne"

There are often acne-like red pimples on the face over amalgam fillings, which distress especially young girls very much. They disappear only after complete amalgam removal.

7.2 Lack of Drive - Depression

Poison-related fatigue is strongest in the morning because detoxification is reduced at night.

There is no amalgam poisoning without lack of drive and chronic fatigue. Mercury and tin have the effect of constant irritation that does not allow the body rest. This includes sleep disorders. This symptom improves most evidently under DMPS, and recurs when the poison relocates; it is therefore one of the indicators for the necessity of renewed antidoting.

In particular cases the symptoms can include even loss of conscience (coma). Without timely DMPS injection and extraction of the amalgam teeth these patients slowly waste away.

7.3 Abdominal Pain

As a result of previous pelvic inflammations or cystitis, young girls

can have excessively high amalgam accumulation in the affected nerves. After DMPS a short relief is experienced, followed by one to three occurrences of strong abdominal pain. Apart from a hot water bottle, Diclofenac (1 suppository 50 mg) helps instantly.

Especially in cases of diarrhea, DMPS and DMSA do not help at once. The pain is caused primarily by the silver in the amalgam, whose effect is alleviated only by amalgam detoxification.

Kidney insufficiency is the classic result of amalgam poisoning. Here capsules are better for detoxification.

The most common result of an amalgam poisoning is fungal infection of the intestines (candida). Often, fungal foci also need to be removed from a mandibular molar (see ch. 3.6 and 4.6).

7.3.1 Liver Damage

Amalgam damages even non-alcoholics by enzyme blockade (coenzyme A), especially when the cell is deficient in zinc, this is an abnormal state of the liver as seen in chronic alcoholism. It disappears completely after correct amalgam removal.

7.3.2 Pancreatic Inflammation

As above, amalgam can cause a rarely identified pancreatic inflammation with diabetic disorder. Here we find foci in the "4" teeth, maxillary.

7.4 Bladder Disorders

Here amalgam can be felt on many levels: strong kidney poisoning, a high concentration in the bladder sphincter, mercury resistant bacteria or a high amalgam concentration in the prostate gland. Amalgam-related cysts in the ovary and womb can complicate the clinical picture, which can range from constant urgency to the necessity for using a bladder catheter by oneself. Often there is a high level of toxin excretion via the stool. After amalgam removal and DMPS an intensive bladder training is necessary.

7.5 Blood Count Abnormalities

Directly and via a chronic inflammation in the blood formation system,

abnormalities of the white blood cells and the thrombocytes can occur. This can become extremely pronounced when there is a parallel poisoning with wood preservatives.

7.6 Depression, Psychosis

Mercury and tin, if accumulated in certain brain areas, cause strong depressions and also delusions. This often ends in suicide. Dentists and workers exposed to mercury (hat makers) have a high suicide rate. It is macabre that psychiatric patients in particular are intensively poisoned with amalgam. Schizophrenic patients have a metabolic disorder concerning mercury: they are able to excrete only little via the urine , instead they excrete most via the intestine. There the highly toxic organic mercury is formed, which poisons especially the brain. In such a case, DMPS sniffed from ampules helps especially well. Since the brain is particularly sensitive to poisons, the lab results after mobilization - even if extremely low - do not give any indication of the severity of the illness, but rather show the improved clinical picture after DMPS. Every amalgam victim has psychological problems. Some learn to deal with them. Schizophrenia affects 1 % of the general population, but 80 % of the amalgam victims.

7.6.1 Drug Addiction

Mercury inhibits the degradation of drugs, for instance by folic acid blockade. As a result of their psychological problems, amalgam victims often slide into a drug addiction. Only after detoxification do they spontaneously come out of it.

7.7 Diarrhea

Swallowed heavy metals always provoke diarrheas in sensitive people, with mercury they can contain pus and blood. A tissue sample of the intestinal mucous membrane can reveal the amalgam components upon analysis.

Since these toxins are in part transformed into organic substances by intestinal bacteria, causing additional and severe brain poisoning via the blood, the intestinal poisoning is then treated psychotherapeutically instead of cause-related. The diagnosis might then be Crohn's disease or Colitis ulcerosa - depending on how advanced the poisoning

is. Without cause removal one remains the faithful patient of the gastroenterologist and psychotherapist.

Here, DMPS should absolutely be injected, and against the intestinal irritation caused by the toxins which are excreted by the liver and gall bladder, medicinal coal (10 grams) should in addition be given.

As long as the intestinal irritation continues, capsules or powder must not be given. Injections enhance the renal excretion and keep intestinal excretion to a minimum. Metals should generally be avoided afterwards.

Zinc should be injected intravenously in regular intervals (zinc aspartate).

An amalgam - related hyperfunction of the thyroid gland can worsen such diarrheas.

7.8 Epilepsy

In case of increased accumulation of amalgam in specific regions of the brain stem, seizures can be provoked if additional factors are present (light, stress). Alcohol in conjunction with methyl mercury strongly increases the tendency towards episodes.

The first DMPS injection can trigger a seizure if the ^{doctor} Δ does not inject an ampule of phenhydant^e_A into the vein beforehand. Long-standing epilepsy demands the extraction of all the teeth that have old amalgam fillings as well as surgical cleaning of toxin depots. DMSA capsules are suitable for long-term detoxification. Here, DMSA is much better suited because of its ability to dislodge organic mercury from the brain.

7.9 Memory Disfunctions

Every nerve poison causes memory disorders. This effect, though, is most pronounced with amalgam and aluminium. A formaldehyde metabolism disorder boosts this effect. Of course 'brain workers' are more sensitive to this. Accompanying symptoms are: mental sluggishness, fear of the new, difficulty in being happy about little things, increased pain sensitivity, submissiveness, flaring temper, a feeling as if being under a glass bowl, inability to perform delicate finger movements. Only after correct amalgam removal will DMSA unfold its excellent effect towards detoxification of the brain. For aluminium poisoning, DMPS (especially sniffed), or Desferroxamine are more effective. Alzheimer's

disease is a result of mercury blocking the acetylcholine synthesis.

7.10 Joint Pains

The silver component in amalgam is responsible for back and joint pain. Often, instead of removing the cause, the symptom - which is of course not the only one of the poisoning - is attacked via surgery. The additional muscular damage caused this way then often leads to further surgery. Lumbago and knee arthritis are most common.

If the joint problems have lasted many years, it is always a dental focus that keeps the inflammatory process alive. Just removing the amalgam, without focus restoration, would not achieve much. Non-believers can always have the silver concentration in the surgery samples analyzed (intervertebral disks !). No metal replacements must be used for the teeth - especially not silver in a gold alloy. Silver is reduced only indirectly by DMPS or DMSA through removal of the co-components, which can be observed clinically in the reduced pain.

7.11 Hair Loss

Hair loss (spot, circular, later on total) is always a combination of (often maternal) amalgam and a formaldehyde metabolism disorder. The process becomes dramatic and often incurable when a dead dental root is treated with formaldehyde. In an OPT of the dental roots one can see the disturbance of the bone metabolism, which in conjunction with amalgam, causes a wide-based inflammation. Even more important than a thorough removal of amalgam is the avoidance of formaldehyde in the jawbone (surgically clean the alveoli of dead teeth) and in the house dust. Alkalisiation (pills/ sodium bicarbonate) and zinc supplements offer temporary help. Better, though, to change the diet towards base-forming and zinc-rich foods. Zinc should be part of the diet for a long time and in the highest dosage.

7.12 Heart Infarction, Heart Rhythm Disorders

Amalgam depots in the 'heart teeth' (8 or 7), that is, mostly in the wisdom teeth, cause heart rhythm disorders in young people through the characteristic effects of mercury. In older people, depending on the extent of additional vascular damage from smoking or amalgam-related constriction of coronary vessels, they are more likely to

cause infarction. Later on, a focus left in a toothless jawbone can very well have the same effect in this spot as the tooth that stood there before.

The symptoms can be rectified instantly, when the toxins are removed as well as their effects. DMPS is better at detoxifying the nerves of the heart than DMSA. Amalgam, being a selenium eater, damages the heart muscle from the first. Once the damage is done, though, selenium does not help (it only helps in the formation of one enzyme - zinc helps with 200 enzymes); only a very thorough amalgam detoxification does.

7.13 Non-resistance to Infections

After only 20 minutes of chewing gum, or drinking a cup of lemonade, amalgam reduces the T-lymphocytes by up to 25 %. This is important for the organism's defense against viruses (AIDS) or bacteria (700 kinds) and fungi (candida).

The demand for zinc for excretion of the constantly ingested, toxic amalgam components leads to a relative zinc deficiency in the cells (white blood cells), where zinc is needed for the formation of 200 defense enzymes. The zinc deficiency also decreases the amount of T-cells.

The location of the dental foci in the jawbone (amalgam, decay teeth) determines the organ in which the infection erupts (paranasal sinuses, stomach, liver, etc). For this reason, amalgam detoxification and zinc supplementation help only if the dental foci are removed. The most common infection sites are the head and the lungs by inhalation, and the kidneys through the amalgam excretion.

7.14 Infertility - Impotence

In the reproductive organs, amalgam can accumulate particularly strongly, and lower the zinc level much. Because of its high enzyme content, semen is the body fluid that is richest in zinc. When a patient has amalgam and a zinc deficiency, the sperm count is reduced or the functioning of the female ova is impaired. Toxin accumulation in the prostate gland, in the ovaries (cysts) and in the womb (myoma) all play a part in preventing the normal growth of the fertilized ova. In many cases the extraction of teeth 14 and 24 with foci has aided pregnancy. Zinc supplementation (iv) after correct amalgam detoxification

can help a lot towards getting pregnant. Before pregnancy, DMPS - therapy after amalgam removal is important. Cadmium, PCP and formaldehyde must also be undetectable in the body.

7.15 Interactions

see ch.3.2 Effect Amplification

7.16 Headaches

Of all nerve poisons, amalgam causes the most head pain, along with lead, cadmium and formaldehyde. In the MRI one can observe brain edemas (hyperpressure due to water accumulation). If the amalgam was in the mouth for only a short time, a correct removal is sufficient for the complete cessation of pain. Longer amalgam exposure demands DMPS injections according to the time passed. Here especially the extraction of formaldehyde-filled teeth is of importance.

The relief from years of headaches is the most delightful effect of an amalgam treatment.

7.17 Cancer

The organic (methyl) mercury that accumulates in some organs (brain, skin, digestive tract, etc) is cancerogenic. Amalgam, being a selenium consumer, simultaneously aids cancer development due to selenium deficiency.

An early sign of a developing cancer is the relative decrease in the number of cells that destroy cancer cells (lymphocyte killer cells).

For identified cancer the complete removal of amalgam depots is sure to prolong life by improving the immunological situation before any relapse.

Even much later, the surgically removed cancer tissue - which must in Germany be kept in the pathological institute for 10 years - can be analyzed to determine the causal amalgam accumulation, and bring re-compensation.

7.18 Paralysis, MS, ALS

Both on OPT and MRI we find the same abnormalities under one-time amalgam teeth in the jawbone. If these abnormalities are also identifiable in the cerebrum and in addition there are high metal concentrations in the jawbone under the extracted teeth, then we must assume that metals are the cause. Therefore, large and small foci in the cerebrum are metal-related inflammation foci that developed. For years we have been observing a large number of patients whose spots in their brain tomographies decreased in size and whose paralytic symptoms (and other so-called MS symptoms) slowly regressed in waves after correct amalgam removal and under constant DMPS injections/ sniffing (see ch. 5.3). Here DMSA powder is absolutely prohibited, because the rapid brain detoxification very often causes the severest episodes. For the same reason, zinc should also be given only with the greatest care (at most: in lowest dosage). We have yet to see one multiple sclerosis patient without amalgam fillings either in him or the mother.

Feer patients must have their amalgam removed under protection.

It is better not to do anything about the amalgam poisoning than to do something wrong, for instance drilling out amalgam instead of pulling the tooth or taking DMSA instead of DMPS or taking selenium, etc..

All nerve poisons must be avoided in these cases (lead, formaldehyde, wood toxins, pyrethroids) !

7.19 Muscle Weakness

Mercury inhibits muscle aldolase, the engine of muscle metabolism, and can lead to inherited muscle diseases due to spot mutations. Since this is an immune disorder, improvement can set in only after complete toxin removal, meaning , it takes a very long time. Zinc helps much in detoxification and is needed in highest dosage. Selenium has no effect. Every amalgam removal causes a worsening of some duration, for this reason the surgical cleaning of the jawbone depots is in most cases unavoidable. In most cases improvement sets in only after 5 years.

Sudden performance drops in athletes could be treated in the same way.

7.2o Pregnancy

What happens during pregnancy, shapes the child for life. Amalgam in the mother, and not only the current but also any previous amalgam, determines the child's sensitivity towards chemicals in general (chemical sensitivity). While in the womb, the baby's blood contains 6 to 30 times the mercury concentration of the mother's blood. During her first pregnancy, a mother detoxifies herself and rids her body of up to 40 % of the total toxins in it (second pregnancy about 5 %). Newborn children have DMPS-test results in urine of up to 2500 µg mercury per gram creatinine - an extremely high level even in adults.

Newborn children are at least 100 times more sensitive to poisons than adults. For mercury there is no certain non-toxic amount for the organism. Mercury damage to infants is well known for more than 70 years as the Feer-syndrome. About 7 % of these children die of it. In the children that live, the most obvious sign is their restlessness, irritability and constant desire to sleep. Later on they suffer from brain disorders. Paradoxically, we have measured the highest concentrations of home toxins - which compound the amalgam's effects - in schools for handicapped children. Those children that are pre-damaged by their mother's amalgam show a considerably higher tendency toward tooth decay than those without metabolic damage.

Then, if amalgam is put into the children's teeth, everything gets much worse. Amalgam in milk teeth poisons the new ingrowing teeth by a factor of up to one million. The already damaged young brain reacts strongly to the renewed mercury assimilation. But the poisoning during the pregnancy is ^{already} enough to cause the infant neural disorders, and a tendency towards infections, to allergies and to various skin diseases.

During pregnancy all dental treatment of amalgam teeth is prohibited; molars with deep fillings should, in case of pain, be extracted after laser pain treatment.

Avoid all amalgam release. zinc aspartate 0-100-0 mg

Detoxification only with zinc (). If the zinc level in the blood cells is too low, a miscarriage is the likely outcome, if zinc was not supplemented sufficiently.

Newborn children are the most helpless amalgam victims.

Congenital amalgam defects:

Blindness, hydrocephalus, cramps (epilepsy), underweight, inhibited development, growth disorders, edemas.

7.21 Vertigo

Vertigo is one of the signs of a very severe chronic mercury poisoning - often in conjunction with a formaldehyde metabolism disorder. DMPS brings immediate temporary relief if there is no complication due to metal foci in the cerebellar region of the MRI or due to a severe poisoning with wood toxins (Lindane-Parkinsonism). Otherwise a comprehensive search for other accumulated environmental toxins is called for. But: amalgam in a single ear tooth (18,17,28,27) can already very well cause vertigo.

7.22 Vision, Hearing and Speech Disorders

Since many of these specific, amalgam-related disorders exist from birth on because of maternal amalgam, the serious deterioration caused by new fillings in the child are not so apparent. Patients see the connection usually only after DMPS, when, for example, suddenly vision improves.

When the symptoms occur later, the "eye tooth"(3) or the "ear tooth" (8,7) must be checked for foci and perhaps extracted. Extracting "eye teeth" comes easily only with older patients or those with an eye tumor; younger patients often refuse this because the prosthesis is inconvenient. For treating the brain depots, DMSA is particularly well suited.

Tinnitus often occurs in connection with dental foci and amalgam plus gold(palladium). The German Tinnitus-League estimates that about 5 million people in Germany suffer from ear noise either constantly or sometimes. Doctors are often helpless.

Stuttering and trouble finding the right word often improve after DMPS.

7.23 Fatalities, Crib Death

Countless patients die of amalgam; some slide into unconsciousness as in a psychomotor attack, others die of nocturnal attacks with respiratory arrest - this being the typical cause of child death in the Sudden Infant Death Syndrome, SIDS. Infections and head injuries bring about sudden deterioration. Some deceased infants have higher concentrations of mercury in their brain and liver than adults (2000 ug/kg). Every year more than 2000 babies die of crib death in Germany.

In deceased amalgam victims the poison can be proven only in the depot organs, especially in tumors.

In Germany every patient proven to have died of this medication is insured for DM 500,000 by the manufacturer. Amalgam as the cause of death must be especially pointed out, since it is not looked for routinely yet today.

7.24 Trembling

Amalgam, much more than all other nerve poisons, causes trembling besides nervousness, if certain areas in the brain stem and the cerebellum have accumulated mercury. If lindane, from wood preservatives, is added to this pre-damage, the result is Parkinson's disease - the same goes for lead and other nerve poisons. Sole amalgam poisoning improves quickly under DMPS and even better under DMSA. Zinc improves the detoxification process.

Alcohol at first improves the condition, but makes it worse in the long run by raising the methyl mercury level in the brain.

7.25 The Constant Complainer

Some patients and even two amalgam information centers sued the author without success, because he allegedly did not help enough in lawsuits against the manufacturers.

All those, who had unsuccessfully sued the amalgam manufacturers, then directed their complaints against those people that had helped them correctly.

People that are poisoned by amalgam can be incredibly egoistic and underhanded.

Amalgam patients often annoy all their doctors, especially those that are willing to help.

Amalgam makes people lament instead of taking decided action. This grouching-complaining behavior has to be regarded as a medical symptom and always taken into account accordingly.

7.26 Psychosomatics

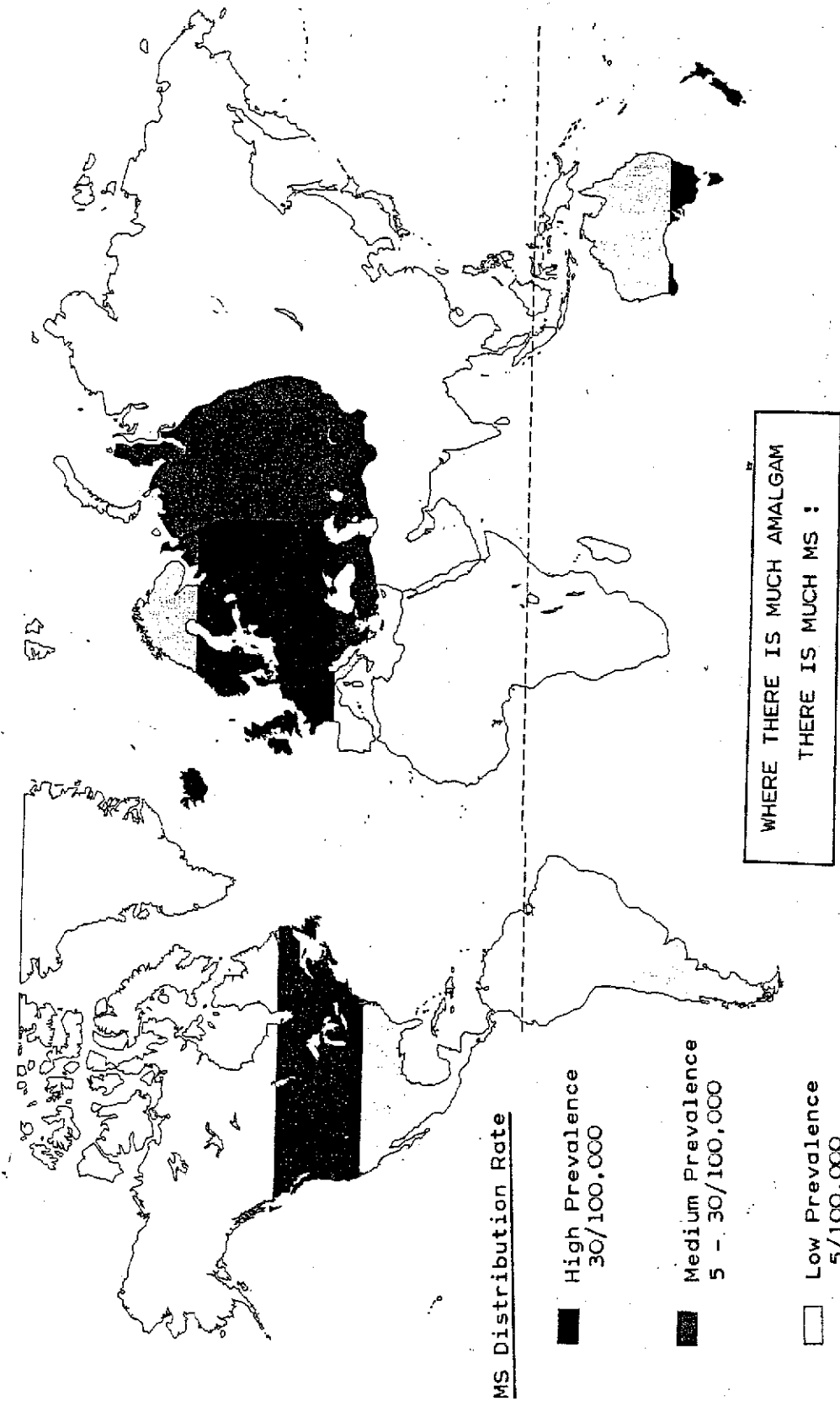
Dental poisons like amalgam cause purulent foci to develop in the jawbone, which irritate cranial nerves and, in turn, lead to organ irritation - the so-called psychosomatic indication.

These psychosomatic symptoms are curable only by removing the pus ("somatic") under the teeth, the nerve irritation ("psycho") will then disappear.

If organic causes of psychological complaints are ignored over a long period of time, or if psychotherapy alone is even attempted, then the usual results are irreversible organic diseases like cancer. If long-life poisons like metals are located in the purulent foci under the teeth, the results are allergies and, in turn, auto-immune diseases, which are also lethal in the long term.

Translation :
Jerusalem, September 2000 Georg Schmidt

„MS“ and Amalgam



The disease is most prevalent in the moderate climate of Europe and North America

(Source : H.Rüttiger "Multiple Sklerose")